

## Placenta Accreta Causing Uterine Rupture in Second Trimester of Pregnancy after in vitro Fertilization: A Case Report

Priya Dahiya<sup>1</sup>, Kanad D. Nayar<sup>1</sup>, Amar J.S.Gulati<sup>2</sup>, Kiran Dahiya<sup>3\*</sup>

1- Akanksha IVF Center, Mata Chanan Devi Hospital, Janak Puri, New Delhi, India

2- Department of General Surgery, Mata Chanan Devi Hospital, Janak Puri, New Delhi, India

3- Department of Biochemistry, Pt. B. D. Sharma Post Graduate Institute of Medical Sciences (PGIMS), Rohtak, Haryana, India

### Abstract

**Background:** Placenta accreta is a rare obstetrical condition that mainly occurs in the third trimester leading to life-threatening complications. Hereby, a case of uterine rupture due to placenta accreta occurring in the second trimester is presented.

**Case Presentation:** A forty-year old patient who conceived after in vitro fertilization treatment (oocyte donation and embryo transfer) presented in emergency department in the nineteen weeks of gestation with acute abdominal pain, hemoperitoneum and fetal death. Emergency laprotomy showed uterine rupture along with placenta accreta for which the patient underwent subtotal hysterectomy.

**Conclusion:** Although, an uncommon occurrence, physicians in assisted reproductive techniques (ART) clinics should consider placenta accreta in gravid patients who present with acute abdominal pain and shock, considering the fact that they usually have associated high risk factors for abnormal placentation.

**Keywords:** IVF, Placenta accreta, Second trimester pregnancy, Uterine rupture.

**To cite this article:** Dahiya P, Nayar KD, Gulati AJS, Dahiya K. Placenta Accreta Causing Uterine Rupture in Second Trimester of Pregnancy after in vitro Fertilization: A Case Report. *J Reprod Infertil.* 2012;13(1):61-63.

\* Corresponding Author:  
Kiran Dahiya, 778/28,  
Bharat Colony, Rohtak,  
Haryana, India  
E-mail:  
kirandahiya\_2002@yahoo.  
com

Received: May. 18, 2011

Accepted: Sept. 26, 2011

### Introduction

The term placenta accreta is used to describe any placental implantation in which there is abnormally firm adherence to the uterine wall. As a consequence of partial or total absence of decidua basalis and imperfect development of the fibrinoid layer, placental villi are attached to the myometrium in placenta accreta, actually invade the myometrium in increta, or penetrate the myometrium in placenta percreta. Although an uncommon condition, abnormal placentation assumes considerable significance clinically because of morbidity and, at times, mortality from severe haemorrhage, uterine perforation and infection (1).

Spontaneous uterine rupture early in course of pregnancy is a very rare complication, more so, in case of patients treated by in-vitro fertilization (IVF). High risk factors are previously scarred uterus, dilatation and curettage, advanced maternal age and abnormal placentation (2). We present

here an interesting case of this potentially life-threatening complication in an IVF conceived patient where placenta accreta led to uterine rupture in second trimester necessitating hysterectomy due to uncontrolled hemorrhage.

### Case Presentation

A 40-year old infertile woman was referred to our center for IVF program (oocyte donation and embryo transfer). She had two previous histories of dilatation and curettage, one after spontaneous abortion and another for diagnostic purposes.

Hysteroscopy was done prior to IVF cycle which revealed a band of adhesion running from anterior to posterior wall for which adhesiolysis was done in the same session. The patient conceived in the second cycle of embryo transfer (oocyte donation). Pregnancy was confirmed by beta-human chorionic gonadotrophin ( $\beta$ -hCG) levels and later on, by ultrasound which confirmed single

intrauterine gestational sac with a beating heart. She was followed up regularly for her obstetric examination with no other risk factors except for advanced maternal age.

Level two obstetric ultrasound examination was done at eighteen weeks of gestation which ruled out gross congenital anomalies and suggested grade 0 left fundo-anterior placenta with normal invasion and normal amniotic fluid. In the nineteenth weeks of gestation, patient presented in the emergency department of our hospital with acute abdominal pain and signs of early shock (pulse rate 180/min, blood pressure 90/60 mmHg, hemoglobin 7.5 g % and hematocrit of 24%).

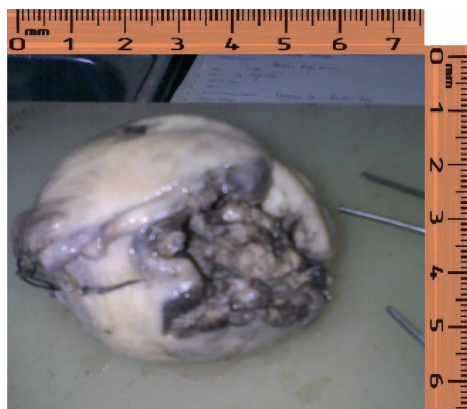
Initially, the patient was revived from shock with adequate fluid replacement and other basic management procedures including central line placement for central venous pressure (CVP) monitoring. Once the patient's condition was stable, she was sent for ultrasound and CT scan evaluations. Ultrasound examination revealed fresh intrauterine fetal death along with hemoperitoneum with no other gross finding.

CT scan was done to rule out other causes of hemoperitoneum. Findings were suggestive of weakening of the uterine musculature at the left fundal region with fetus inside the cavity. Patient was taken up for emergency laprotomy and a hemoperitoneum of 3000 ml was found along with a dead fetus coming out of a large uterine fundal defect. Female fetus of approximately 700 g was extracted but the placental tissue could not be separated from the myometrium. Subtotal hysterectomy was performed in view of massive haemorrhage, while all other intra-peritoneal organs were found to be intact. The patient was transfused one unit of packed cell intra-operatively and two units thereafter. She was intensively monitored postoperatively and was discharged on the sixth post-operative day in a perfectly stable condition.

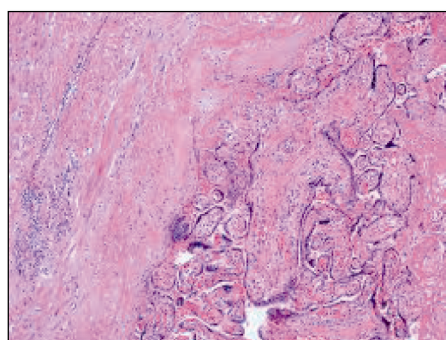
Uterus (Figure 1) sent for biopsy and pathology report showed chorionic villi reaching the myometrium with absent decidua basalis which were consistent with the diagnosis of placenta accreta (Figure 2).

### Discussion

Review of the literature suggested incidence of abnormal placentation, including placenta percreta, to be varying between 1 in 540 and 1 in 93000 with an average of 1 in 700. Recently, incidence of placenta accreta is on rise due to in-



**Figure 1.** Post operative specimen of uterus showing large fundal defect



**Figure 2.** Histopathological image of uterine tissue showing chorionic villi invading myometrium and absence of decidua basalis.

creased number of caesarean section in modern obstetrics (1).

Spontaneous rupture of the uterus due to placenta percreta is one of the most urgent obstetrical complications resulting in rapid exsanguination and high mortality which is more commonly seen in the third trimester and is very rare in second trimester (3). It is rarely recognized intrapartum and is very difficult to diagnose.

Suspicion arises in case of unexplained elevation of alpha-fetoprotein (AFP) (4). Ultrasound (findings in percreta) and MRI can give more details leading to further suspicion of such an abnormal placenta. We could not perform MRI and AFP in our patient as placental pathology was not suspected for the disease in the first place.

The precise etiology of all cases of placenta accreta is unknown, however, there are known factors that increase the risk. Greatest among them are scarring of endometrial cavity with previous caesarean section, uterine curettage, myomectomy, Asherman's syndrome, iatrogenic uterine perforation and advanced maternal age. These risk factors are frequently seen in IVF/embryo transfer

candidates.

In most cases, placenta accreta is caused by a combination of factors and its occurrence is unlikely to be attributed to a single factor.

In contrast to many reports, in which a placenta percreta was diagnosed in patients with previously scarred uterus (5, 6), our patient had no history of previous caesarean section. However, less significant factors like advanced maternal age and history of curettage may have been the cause in this patient. Spontaneous uterine rupture in early gestation is extremely rare. Cases of spontaneous uterine rupture as a result of placenta percreta during early pregnancy have been reported during 10<sup>th</sup> to 20<sup>th</sup> week of gestation, but amongst them only few involved healthy patients with non-scarred uterus (2, 7).

Important differential diagnoses in suspected cases when placenta could not be separated postpartum include retained incarcerated placenta, adherent placenta where there is a line of cleavage and choriocarcinoma. Histopathology has been found to be the gold standard of making the final diagnosis (4, 7).

Therefore, it may be concluded that one has to be very careful and keep the possibility of placenta accreta while dealing with IVF conceived pregnancies as the incidence of above discussed risk factors in most of infertile patients is high. Ultrasonography and colour Doppler study for the diagnosis of site of placentation along with maternal serum alpha fetoprotein measurement in doubtful cases of placenta accreta seems to be necessary as early diagnosis renders conservative treatment possible.

**Informed Consent:** Informed consent of the patient was obtained beforehand.

### Acknowledgement

There was no conflict of interest regarding the presented material in this article.

### References

1. Khong TY. The pathology of placenta accreta, a worldwide epidemic. *J Clin Pathol.* 2008;61 (12): 1243-6.
2. LeMaire WJ, Louisy C, Dalessandri K, Muschenheim F. Placenta percreta with spontaneous rupture of an unscarred uterus in the second trimester. *Obstet Gynecol.* 2001;98(5 Pt 2):927-9.
3. Levrant SG, Wingate M. Midtrimester uterine rupture. A case report. *J Reprod Med.* 1996;41(3):186-90.
4. Kupfermanc MJ, Tamura RK, Wigton TR, Glassenberg R, Socol ML. Placenta accreta is associated with elevated maternal serum alpha-fetoprotein. *Obstet Gynecol.* 1993;82(2):266-9.
5. Höpker M, Fleckenstein G, Heyl W, Sattler B, Emons G. Placenta percreta in week 10 of pregnancy with consecutive hysterectomy: case report. *Hum Reprod.* 2002;17(3):817-20.
6. Endres LK, Barnhart K. Spontaneous second trimester uterine rupture after classical cesarean. *Obstet Gynecol.* 2000;96(5 Pt 2):806-8.
7. Morken NH, Henriksen H. Placenta percreta--two cases and review of the literature. *Eur J Obstet Gynecol Reprod Biol.* 2001;100(1):112-5.