



Chromosomal Analysis of Cumulus Cells as a Future Predictor for Oocyte Aneuploidy: A Case Report

Xavier Viñals Gonzalez ^{1,2*}, Rabi Ahmed-Odia ¹, Sioban Sen Gupta ², Roy Pascal Naja ², Falak Arshad ³, Paul Serhal ¹, Wael Saab ¹, Srividya Seshadri ¹

1- Department of Embryology, The Centre for Reproductive and Genetic Health, London, UK

2- Institute for Women's Health, University College London, London, UK

3- School of Medicine, Cardiff University, Cardiff, UK

Abstract

Background: Within the ovary, the optimal growth of the follicle, oocyte maturation and ovulation are highly conditioned by the two-way cross talk and interactions between the oocyte and the immediate somatic cells, known as cumulus cells (CCs). This biological communication between cell lines triggered the interest in the study of CCs as a biomarker of oocyte competence.

Case Presentation: The findings of a 45,X mosaic pattern on CCs from a female patient with unremarkable medical history are reported in this study. The patient came to the Centre for Reproductive and Genetic Health, London on 14th August 2019 for her first visit and the follow up procedures were done for her to determine underlying genetic status. For this purpose, four sources of DNA including CCs, blood lymphocytes, buccal cells and immature oocytes were analyzed in the present report.

Conclusion: In the present case study, the hypothesis of the female patient being mosaic 45,X was confirmed although the degree of mosaicism and whether this was affecting the germinal line could not be determined. In the event of the discovery of a cell line with an apparently abnormal genetic makeup, genetic counselling is important in order to understand the implications from somatic to germinal cells for patients exploring fertility journeys.

Keywords: Biomarker, Counselling, DNA, Genetics, Mosaicism, Oocytes.

To cite this article: Gonzalez XV, Ahmed-Odia R, Gupta SS, Naja RP, Arshad F, Serhal P, et al. Chromosomal Analysis of Cumulus Cells as a Future Predictor for Oocyte Aneuploidy: A Case Report. *J Reprod Infertil.* 2021;22(2):138-143. <http://dx.doi.org/10.18502/jri.v22i2.5803>.

* Corresponding Author:
Xavier Viñals Gonzalez,
Embryology Department,
The Center for
Reproductive and Genetic
Health 230-232 Great
Portland St, London, UK
E-mail:
xavier.vinalsgonzalez@
crgh.co.uk

Received: Jun. 7, 2020
Accepted: Oct. 11, 2020

Introduction

During early foetal life, cells that will develop into primary oocytes become rapidly enclosed by a subpopulation of somatic cells. These cells will be required to meet the demands of the growing oocytes during their development. Although primary oocytes can remain quiescent for years and are arrested in meiotic prophase I, a small percentage of them are recruited throughout life, even during pregnancy and non-ovulation periods to sustain the reproductive function (1). After resumption of meiotic maturation, changes in both somatic and germ cell lines take place. The dominant follicle will contain the oocyte des-

igned to be ovulated, which will progress through meiosis until it arrests for the last time at the metaphase II (MII) stage waiting to be fertilized by a sperm whilst the other recruited follicles will undergo atresia. Concomitantly, somatic cells differentiate to different populations, but some (Cumulus cells (CCs)) will remain in close physical contact with the oocyte.

The presence of transzonal projections emerging from CCs along follicle development establishes a two-way cross talk and interactions with the oocyte. This biological communication between cell lines triggered the interest in the study of CCs as a

biomarker of oocyte competence. Although research in transcriptomics has proven to be an exciting field with the potential to understand oocyte biology (2–4), there is currently a lack of consensus on the gene(s) that could serve as potential biomarkers in CCs. Currently, there is limited evidence on the use of CCs to determine germinal aneuploidy status. This case provides guidance to focus on proper follow-up investigations when a different cell line in a female patient is observed. This case report is about using the current gold standard next generation sequencing (NGS) combined with conventional karyotyping techniques to evaluate the underlying genetic status of an individual.

Case Presentation

A 37-year-old single woman presented to the Centre for Reproductive and Genetic Health, London (UK) on 14th August 2019 for fertility cryopreservation. Ethical approval (10/H0709/26) and patient written consent was obtained in relation to this publication. She had no previous history of pregnancy or family history of premature menopause. Her medical history was unremarkable and

her body mass index was 27.83 kg/m^2 (Normal). Her ovarian reserve test revealed an anti-Müllerian hormone of 3.9 pmol/l and follicle stimulating hormone of 7.0 IU/L . The patient underwent three cycles of controlled ovarian stimulation to optimize the yield of oocytes. An antagonist protocol was prescribed with Menopur® 450 IU for both cycles. Vaginal oocyte retrieval was carried out 37 hr post Gonasi® (10,000 IU) trigger and a total of six oocytes were collected in the first cycle. Removal of cumulus cells was performed 39–41 hr post trigger by exposure to cumulase (Origio Specialty Pharma, Denmark). Four oocytes were mature (MII) and two were found to be at the germinal vesicle (GV) stage. Cumulus cells were transferred into a HEPES media with microdrops overlaid with oil and used for training purposes to optimize a technique of cell amplification. Different concentrations containing three, four, six and eight CCs and a blank were placed into microcentrifuge tubes containing BSA/PBS buffer. Amplification was successful in three out of the four samples after next generation sequencing (NGS) using Ion ReproSeqPGS kits (Thermo Fisher Scientific Inc., US) (Figure 1). The sam-

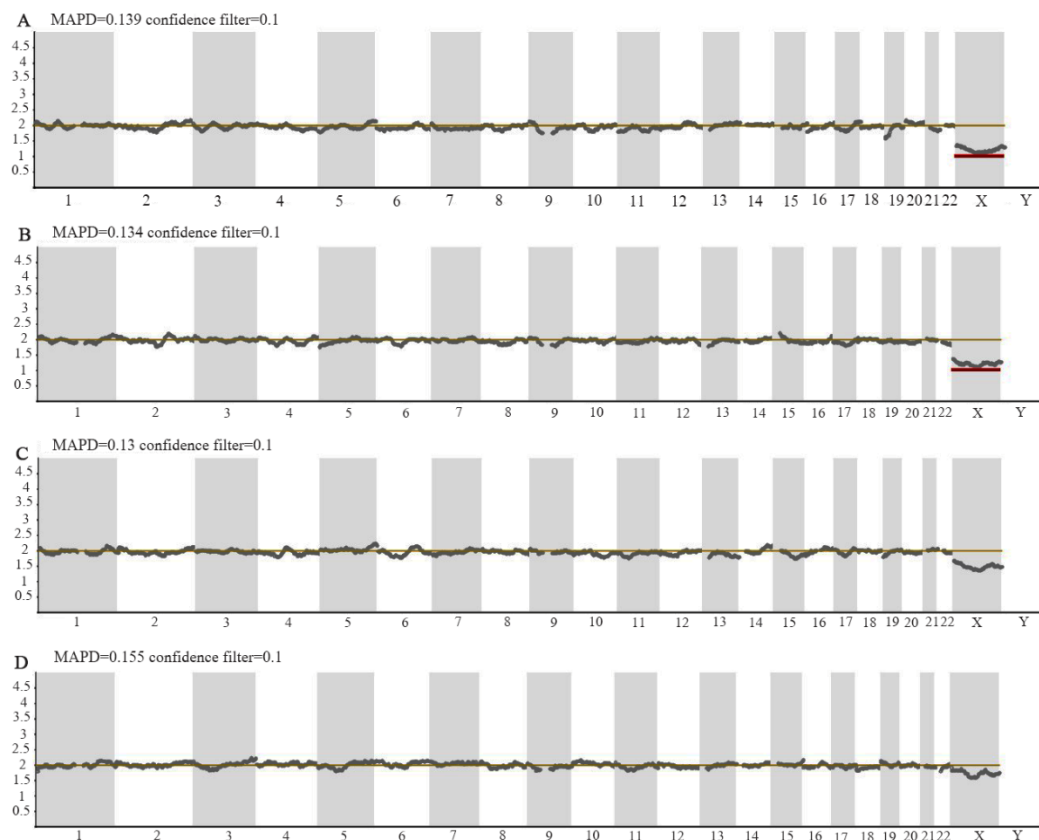


Figure 1. Next generation sequencing profiles for cumulus samples containing (A) four, (B) six and (C) eight cumulus cells and sample containing buccal cells (D). Profiles a and b showed a missing copy for chromosome X (Red line). Other profiles (c-d) showed a normal female chromosome complement

ples containing four and six CCs showed a 45,X complement in the NGS profile whilst the one with eight cells showed 40-50% mosaicism for the same chromosomal aberration.

The patient was informed of the findings and a karyotype was strongly recommended for further clarification, since the patient had presented with low ovarian reserve parameters. An apparently normal female chromosome complement (46,XX) and banding pattern was noted after standard analysis on 5 metaphase lymphocyte cells (Supplemental Figure 1). In view of the referral indication, an extended screening of sex chromosomes was performed on a total of 50 metaphase cells where in two cells (4%), a complement of 45 chromosomes was seen with a single cell copy (Monosomy) of the X chromosome and in 48 (96%) cells, an apparently normal female chromosome complement was observed. A second cycle was performed following the same protocol resulting in five oocytes namely four MII stage and one metaphase I (MI) stage oocytes. The immature MI oocyte was subjected to the same NGS protocol as previously done on the cumulus cells in order to understand the origin of the mosaicism detected in the CCs. A third cycle was performed resulting in six oocytes, four MII stage, one MI and one GV. Immature oocytes were subjected to NGS protocol. A normal chromosome complement was noted in the immature oocytes (Supplemental Figure 2). In order to investigate the extent of somatic/germline mosaicism, a buccal swab was requested and sent for further NGS analysis. Extracted DNA from epithelial cells was diluted to 40 pg/ μ l and 2.5 μ l were subjected to NGS. Results showed a 21% mosaicism for the 45,X complement (Figure 1). Results were conveyed to the patient and genetic counselling was provided to explain the implications of these findings and the repercussion on her fertility journey.

Discussion

The presence of CCs with Turner Syndrome (TS) genotype led the team to refer the patient to a blood chromosome study. According to a study by Russell et al., for a patient aged 37 years, the reportable range for X chromosome loss within peripheral blood cultures would be 6% or above (5). At the observed level of 4%, the laboratory could not differentiate between genuine mosaicism, age related X loss or technical artefact. Interestingly, a previous report in literature has shown a patient diagnosed with non-mosaic TS following karyo-

typing of 50 lymphocyte cells being re-diagnosed as mosaic TS after observing a larger number of cells from different tissues using FISH (6). Hence, the observation of higher number of blood lymphocytes could show various genotype patterns.

The detection of 45,X cells in a different tissue sample (Somatic cumulus cells) was initially done in our patient with no apparent abnormal phenotype. Although the differentiation of age-related loss versus genuine mosaicism is challenging, discovering aneuploid cells in a second somatic tissue (Buccal epithelial cells) would favor the latter. A normal female chromosome complement was noted in one metaphase I oocyte. A recent study including ovarian follicles from 5 female individuals with TS revealed that some oocytes were found to be normal after X chromosome analysis although granulosa cells were largely monosomic (7). Hematopoietic stem cells such as lymphocytes arise from the lateral mesoderm and granulosa cells are derivatives from the intermediate mesoderm (8). Given that germ cells (Oocytes) also have their origin in the intermediate mesoderm, a certain degree of mosaicism could be expected. Peek et al. (9) also noted 45,X oocytes in human, although it has been highlighted in literature that oocytes may escape meiotic sex chromosome inactivation at higher frequency than spermatocytes (10). From the present case study, the validity of CCs as a tool for oocyte aneuploidy can be confirmed. However, validity of CCs chromosomal analysis as a predictive tool for oocyte aneuploidy should be further explored in larger research studies. Interestingly, the sample containing the lowest concentration of CCs failed to amplify, which highlights the need to determine the integrity and viability of such cells before tubing for analysis (Figure 2).

Genetic mosaicism is classically defined as the coexistence of clonal cellular populations harboring two or more distinct genotypes (11). In our case, the hypothesis of the female patient being mosaic 45,X was confirmed although the degree of mosaicism and whether this was affecting the germinal line could not be determined. In the circumstances reported in this manuscript, when aneuploidy is detected in cumulus cells, different steps ought to be taken: (a) the request for an extended karyotype (≥ 50 lymphocyte metaphases) as standard analysis does not necessarily exclude small rearrangements, low level mosaicism or microdeletions (Note that to detect 10% mosaicism with 99% confidence, 44-48 cells should be

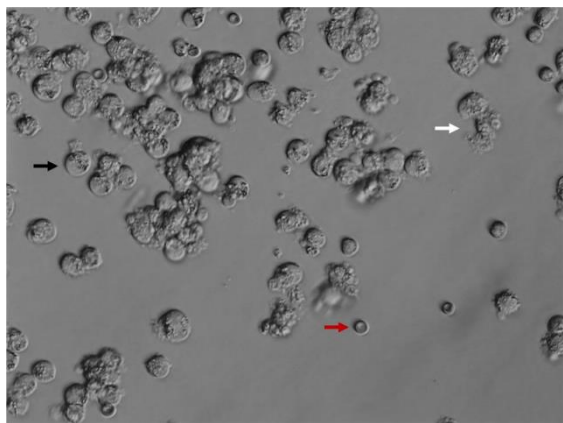


Figure 2. Cumulus cells obtained after decumulation. Note the difference of cumulus cells (Black arrow) from lysed cumulus cells (White arrow) and erythrocytes (Red arrow) prior to sample tubing for genetic analysis

analyzed) (12); (b) if possible, any immature oocytes harvested should be sequenced to understand the degree of germinal mosaicism taking into account the tetraploid and diploid complement expected of GV and MI stage oocytes, respectively; (c) as X chromosome loss has been reported to be a tissue specific phenomenon (13), analyzing another tissue sample (Buccal epithelial cells) is important particularly in cases of low or restricted mosaicism; (d) the results must be reported to the patient at all stages and genetic counselling should be recommended.

Aller et al. reported the hereditary nature of mosaic forms associated with partial Turner Syndrome (14). From a counselling perspective, there is the possibility that the patient may not want to find her genotype or continue with any further testing. Therefore, pre-test counselling is imperative and follow up post-test counselling must be arranged to ensure proper understanding. Additionally, exploration of these findings may impact other family members; therefore, a discussion around how to relay this information may be of importance taking into account socio-cultural factors. It is key for individuals diagnosed with any form of TS to understand the effects on fertility including gonadal failure and their future offspring. Cases of mosaic TS woman delivering infants with normal karyotype have been previously reported (15, 16). Preimplantation genetic testing may be an option to decrease the chance of aneuploidy in offspring. In the event of fertility preservation, Goldman et al. provided live birth predictions by age and number of mature oocytes (17). For a female patient aged 37 years, 12 mature fro-

zen oocytes can be provided with a 56% chance of ending up with at least one live birth. Similarly, Cil et al. provided an age-specific probability of live birth considering the number of oocytes thawed (18). According to their original data, thawing 4-6 oocytes ought to provide the patient a live birth probability of about 15.1-16.1%. It is noteworthy that such models may not entirely fit individuals with an increased predisposition or risk to chromosomal aneuploidies and should be used with caution as a counselling tool.

Conclusion

Defining biomarkers for oocyte aneuploidy is of general interest, although the Evaluation of oocyte Euploidy by Microarray analysis (ESTEEM) trial highlighted that the clinical utility of inferring aneuploidy in oocytes is limited for embryo ploidy and live birth outcomes (19). Case studies can be helpful in reporting rare occurrences and understanding fertility in 45,X patients. From the present case study, validity of cumulus cells as a predictive tool for oocyte aneuploidy could not be confirmed and it should be further explored in larger research studies. To allow comparisons between tissues, an increased number of metaphase spreads for blood lymphocytes should be taken into consideration. Similarly, increasing the number of cumulus cells for analysis ought to elucidate whether a certain aneuploidy is originated during granulosa expansion, mosaicism, or technical artefact use. In the event of the discovery of a cell line with an apparently abnormal genetic makeup, genetic counselling is strongly recommended to understand its implications in germinal line (oocytes) in patients exploring fertility journeys.

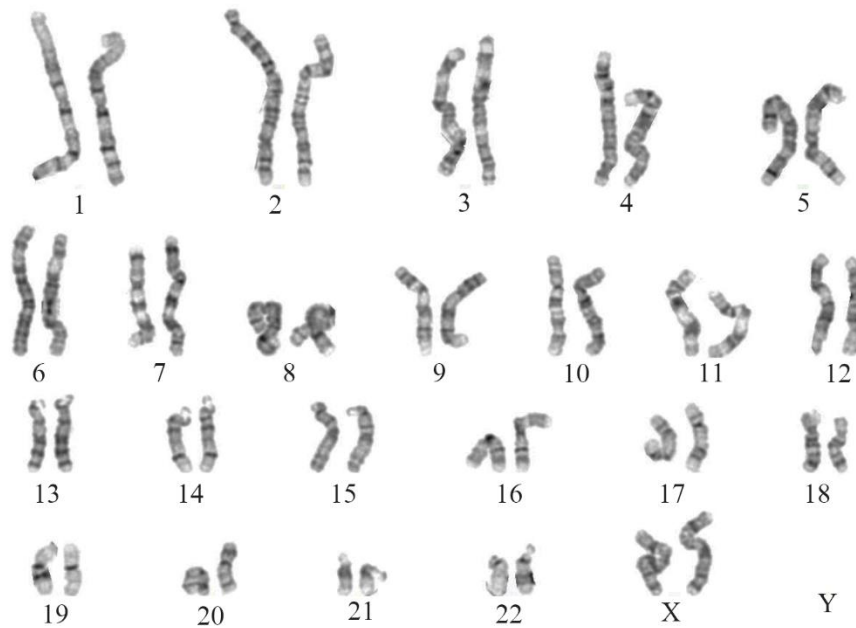
Conflict of Interest

The authors declare that they have no conflict of interest.

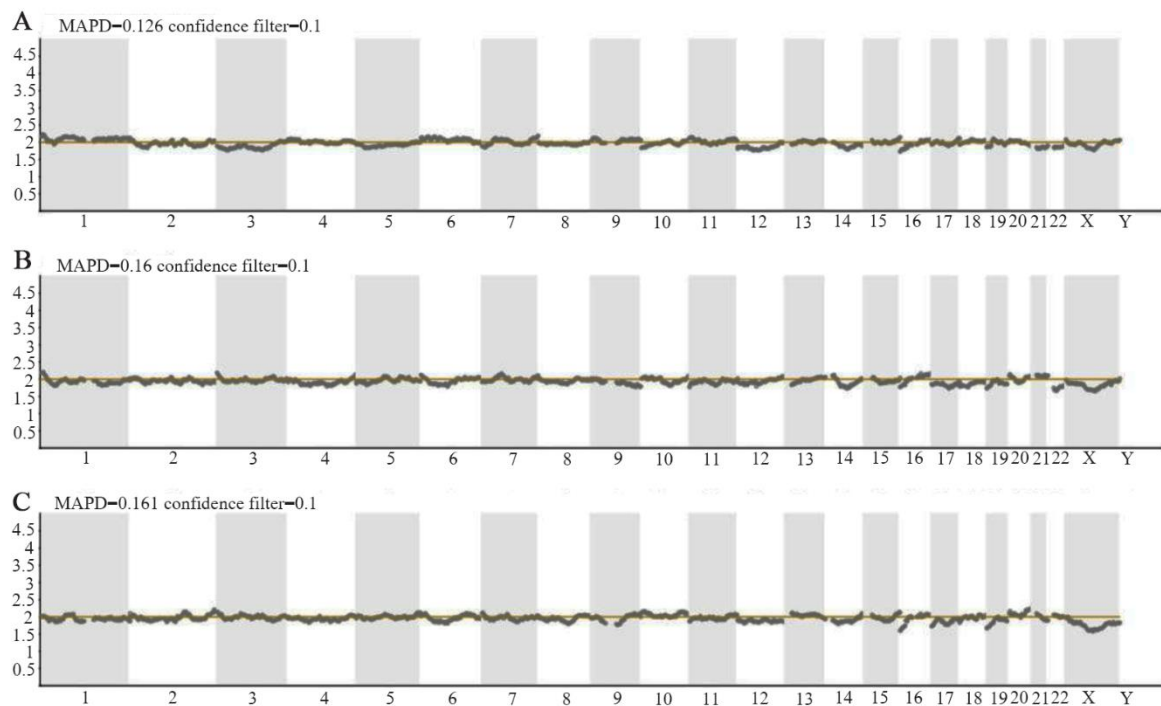
References

1. Son WY, Das M, Shalom-Paz E, Holzer H. Mechanisms of follicle selection and development. *Minerva Ginecol.* 2011;63(2):89-102.
2. Assou S, Haouzi D, Mahmoud K, Aouacheria A, Guillemin Y, Pantesco V, et al. A non-invasive test for assessing embryo potential by gene expression profiles of human cumulus cells: a proof of concept study. *Mol Hum Reprod.* 2008;14(12):711-9.
3. Feuerstein P, Puard V, Chevalier C, Teusan R, Cadoret V, Guerif F, et al. Genomic assessment of hu-

- man cumulus cell marker genes as predictors of oocyte developmental competence: impact of various experimental factors. *PLoS One*. 2012;7(7):e40449.
4. Fragouli E, Wells D, Iager AE, Kayisli UA, Patrizio P. Alteration of gene expression in human cumulus cells as a potential indicator of oocyte aneuploidy. *Hum Reprod*. 2012;27(8):2559-68.
 5. Russell LM, Strike P, Browne CE, Jacobs PA. X chromosome loss and ageing. *Cytogenet Genome Res*. 2007;116(3):181-5.
 6. Sugawara N, Kimura Y, Araki Y. Case report: a successful pregnancy outcome in a patient with non-mosaic Turner syndrome (45, X) via in vitro fertilization. *Hum Cell*. 2013;26(1):41-3.
 7. Peek R, Schleedoorn M, Smeets D, van de Zande G, Groenman F, Braat D, et al. Ovarian follicles of young patients with Turner's syndrome contain normal oocytes but monosomic 45,X granulosa cells. *Hum Reprod*. 2019;34(9):1686-96.
 8. Gilbert SF. *Developmental Biology*. 6th ed. Sunderland (MA): Sinauer Associates; 2000.
 9. Peek R, Schleedoorn M, Smeets D, van de Zande G, Groenman F, Braat D, et al. Ovarian follicles of young patients with Turner's syndrome contain normal oocytes but monosomic 45,X granulosa cells. *Hum Reprod*. 2019;34(9):1686-96.
 10. Turner JMA. Meiotic silencing in mammals. *Annu Rev Genet*. 2015;49:395-412.
 11. Machiela MJ, Zhou W, Karlins E, Sampson JN, Freedman ND, Yang Q, et al. Female chromosome X mosaicism is age-related and preferentially affects the inactivated X chromosome. *Nat Commun*. 2016;7:11843.
 12. Hook EB. Exclusion of chromosomal mosaicism: tables of 90%, 95% and 99% confidence limits and comments on use. *Am J Hum Genet*. 1977;29(1):94-7.
 13. Deng X, Berletch JB, Nguyen DK, Distèche CM. X chromosome regulation: diverse patterns in development, tissues and disease. *Nat Rev Genet*. 2014;15(6):367-78.
 14. Aller V, Gargallo M, Abrisqueta JA. Familial transmission of a duplication-deficiency X chromosome associated with partial Turner syndrome. *Clin Genet*. 1995;48(6):317-20.
 15. Held KR, Kerber S, Kaminsky E, Singh S, Goetz P, Seemanova E, et al. Mosaicism in 45,X Turner syndrome: does survival in early pregnancy depend on the presence of two sex chromosomes? *Hum Genet*. 1992;8(3):288-94.
 16. Varela M, Shapira E, Hyman DB. Ullrich-Turner syndrome in mother and daughter: prenatal diagnosis of a 46,X,del(X)(p21) offspring from a 45,X mother with low-level mosaicism for the del(X)(p21) in one ovary. *Am J Med Genet*. 1991;39(4):411-2.
 17. Goldman RH, Racowsky C, Farland LV, Munné S, Ribustello L, Fox JH. Predicting the likelihood of live birth for elective oocyte cryopreservation: a counseling tool for physicians and patients. *Hum Reprod*. 2017;32(4):853-9.
 18. Cil AP, Bang H, Oktay K. Age-specific probability of live birth with oocyte cryopreservation: an individual patient data meta-analysis. *Fertil Steril*. 2013;100(2):492-9.e3.
 19. Verpoest W, Staessen C, Bossuyt PM, Goossens V, Altarescu G, Bonduelle M, et al. Preimplantation genetic testing for aneuploidy by microarray analysis of polar bodies in advanced maternal age: a randomized clinical trial. *Hum Reprod*. 2018;33(9):1767-76.



Supplemental Figure 1. Normal female chromosome complement (46, XX) and banding pattern in standard blood chromosome analysis



Supplemental Figure 2. Next generation sequencing profiles for immature oocytes. Immature oocytes from the last two cycles were sequenced: (A) MI stage – second cycle, (B) GV and (C) MI stage from third cycle. A normal complement was described for all three oocytes