



A Novel Familial Case Report of Genetic Syndrome Mimicking Congenital TORCH infections; Pseudo-TORCH Syndrome 2

Iram Sehrish, Tella Sunitha, Avvari Srilekha, Aayushi Gupta, Pratibha Nallari, Ananthapur Venkateshwari *

- Institute of Genetics and Hospital for Genetic Diseases, Osmania University, Telangana, India

Abstract

Background: Pseudo-TORCH syndrome (PTS) is a group of autosomal recessive disorders that clinically and radiologically mimic TORCH congenital infections. The prevalence of pseudo-TORCH syndrome 2 is 1 in 1,000,000 cases worldwide. This novel disorder is extremely rare, and is generally detected by prenatal diagnosis through next generation sequencing (NGS) during pregnancy. In this study, a familial case of pseudo-TORCH syndrome 2 with novel non-sense mutation in the ubiquitin-specific peptidase 18 (USP 18) gene in the parents was reported, who are heterozygous asymptomatic carriers; however, all children have inherited a homozygous pathogenic form of USP18, which is an important negative regulator of type I interferon (IFN) signal transduction. To the best of our knowledge, this is the first case of a novel mutation of USP18 seen in a family with pseudo-TORCH syndrome 2 (PTS 2) from India.

Case Presentation: A 23-year-old pregnant woman with bad obstetric history, including intrauterine and neonatal mortality was referred to the Institute of Genetics in the year 2021 for clinical and genetic evaluation. Advanced clinical exome sequencing of the parents and the fetus revealed heterozygous carrier status in parents and homozygous mutation in USP 18 gene in the progeny leading to pseudo-TORCH-2 syndrome.

Conclusion: The present case highlights the significance of carrier screening, prenatal diagnosis, and genetic counseling in couples with bad obstetric history for the detection of rare genetic disorders with poor prognosis.

Keywords: Next generation sequencing, Prenatal diagnosis, Pseudo-TORCH syndrome 2, Type I interferon signal transduction, Ubiquitin-specific peptidase 18.

To cite this article: Sehrish I, Sunitha T, Srilekha A, Gupta A, Nallari P, Venkateshwari A. A Novel Familial Case Report of Genetic Syndrome Mimicking Congenital TORCH infections; Pseudo-TORCH Syndrome 2. *J Reprod Infertil.* 2022;23(2):135-138. <https://doi.org/10.18502/jri.v23i2.8999>.

* Corresponding Author:
Ananthapur Venkateshwari,
Associate Professor,
Institute of Genetics and
Hospital for Genetic
Diseases, Osmania
University, Telangana,
India
E-mail:
venkateshwari@yahoo.com

Received: Jul. 26, 2021
Accepted: Dec. 25, 2021

Introduction

Pseudo-TORCH syndromes (PTS) are a group of autosomal recessive disorders that clinically and radiologically mimic TORCH congenital infections which were first described by Baraitser et al. (1). The incidence of all pseudo-TORCH disorders is less than one in a million globally (2), and till date no cases have been reported from India. The pseudo-TORCH syndrome is a multisystemic disorder characterized by findings of the central nervous system that mimic

those of congenital intrauterine infections although serological tests are negative (3) for classic TORCH infections (toxoplasmosis, rubella, cytomegalovirus, herpes and syphilis) as well as brain malformations, intrauterine growth retardation, respiratory failure, seizures, and septic shock in neonates. A repeated negative TORCH profile in cases of intrauterine and neonatal mortality is indicative for the diagnosis of this syndrome, and the importance of intracranial calcification and

neonatal seizures is emphasized as a diagnostic assistance. Mutations in the USP18 gene lead to inappropriate activation of the interferon (IFN) immunological pathway and cause TORCH syndrome. Type I interferonopathies are monogenic autoinflammatory disorders described by an increased production or response to type I interferons. USP18 inhibits type I interferon signaling by preventing Janus-associated kinase 1 (JAK1) from binding to the type I interferon receptor. The deficiency of USP18 causes unregulated interferon-mediated inflammation, which is fatal during the perinatal period (4).

Case Presentation

A third-degree consanguineous couple with 4 years of married life and a chief complaint of bad obstetric history including intrauterine and neonatal deaths were referred to the Institute of Genetics and Hospital for Genetic Diseases, India for clinical and genetic evaluation. The couple's physical and clinical examination were normal, and the obstetric history included intrauterine and neonatal deaths with no family history of any genetic abnormalities (Figure 1). The study was approved by institutional ethics committee and the informed consent was obtained from the couple before including in the study. The woman's reproductive history shows the first pregnancy (2018) was uncomplicated until 26 weeks of gestation followed by preterm premature rupture of membranes (PPROM), resulting in preterm birth and the death of the female child (IV-1) 5 days after birth.

The second pregnancy (2019) was uneventful until the woman suffered a PPROM at 30 weeks of gestation, resulting in a premature delivery. This neonate had seizures, a dilated third ventricle, corpus callosum with wavy appearance, and echogenic brain parenchyma. Periventricular leukomalacia was revealed on postnatal MRI and small intestinal obstruction along with unconjugated hyperbilirubinemia, no dysmorphic features, and negative TORCH profile were the other findings. It was suggested that the child (IV-2) died of sepsis 7 days after delivery.

The third pregnancy (2020) was an intrauterine death (IUD, IV-3) at 5 month of gestation. The fourth pregnancy (2021) continued smoothly with normal results of targeted imaging for fetal anomalies (TIFFA) and nuchal translucency (NT) scan. After 17 weeks, an amniocentesis was performed for prenatal diagnosis. The fetus (IV-4) died in utero at 26 weeks of gestation and was aborted.

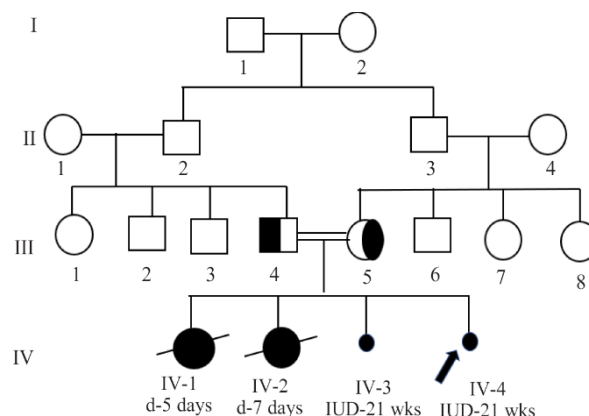


Figure 1. Four generation pedigree of a family with pseudo-TORCH syndrome

Results

The IV-1 female infant sample was unavailable for testing since the neonate died five days after birth. The clinical exome sequencing of the second child (IV-2) revealed a novel homozygous nonsense mutation in exon 9 of the USP18 gene, which resulted in a stop codon and premature truncation of protein (Ubiquitin, p:Tyr302Ter) (Figure 2). Interpretation of pathogenic variant was reported based on the recommendations of American College of Medical Genetics (5). Carrier status of the parents was then assessed, and it was determined that the parents were asymptomatic heterozygous carriers of the same pathogenic variant of the USP18 gene. The prenatal diagnosis by next generation sequencing (NGS) of USP18 mutations for IV-4 indicated that the fetus had inherited USP18 in homozygous form, indicating that the fetus was affected by this autosomal recessive disorder.

Discussion

Pseudo-TORCH syndrome 2 is a severe neurological disorder with an early onset (perinatal)

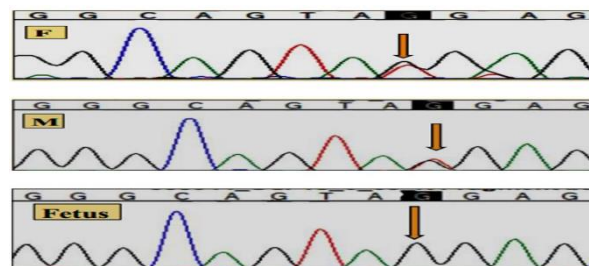


Figure 2. Parents (F and M) whole exome sequencing (WES) indicating heterozygous USP18(+) Exon 9 c.906 T>G (p.Tyr302 Ter) and fetal WES indicating homozygous USP18(+) Exon 9 c.906 T>G (p.Tyr302 Ter)

marked by cerebral calcification, white matter abnormalities, and microcephaly, which mimics congenital viral infections (3). The high rate of consanguinity in PTS families implies that many instances are hereditary, with an autosomal recessive pattern of inheritance. The spectrum of clinical findings includes microcephaly, seizures, brain atrophy, intracranial calcifications (6), hepatosplenomegaly, thrombocytopenia (7), and developmental delay. Pseudo-TORCH syndrome exhibits genetic heterogeneity with three different forms based on pathogenic variation (8, 9). Pseudo-TORCH syndromes have an extremely rare incidence and prognosis with neonatal mortality occurring during the first year of life, as well as significant developmental delay and other clinical symptoms.

Pseudo-TORCH syndrome 2 is genetically heterogeneous with a nonsense mutation in the USP18 gene acting as one of the pathogenic forms which maps to chromosome 22q11.2 in human. Ubiquitin-specific peptidase 18 (USP18) is known as ISG15 isopeptidase and is a negative regulator of type I and type III interferon signal transmission. The expression of USP18 is evident at various levels in different tissues, with a high expression of USP18 detected in the liver, spleen, and thymus (10). However, there was a low but clearly identifiable amount of USP18 expression in bone marrow, adipose tissue, and lung tissue (11). A severe type I interferonopathy is ubiquitin-specific peptidase 18 (USP18) deficiency which inhibits. USP18 inhibits type I interferon signaling by preventing Janus-associated kinase 1 (JAK1) pathway from binding to type I interferon receptor. The lack of USP18 causes unrestricted interferon-mediated inflammation, which is fatal during the perinatal period.

A study conducted by Malakhova et al. (2003) in knockout mice reveals that USP18 deficiency causes severe type I interferonopathy, resulting in neonatal mortality (12), neurological symptoms and brain inflammation, suggesting that a deficiency of USP18 has an effect on the central nervous system that varies in intensity depending on the genetic background (13).

In 2016, a case study was conducted by Meuwissen et al. in two distinct families; in the Turkish consanguineous family, three children were affected by PTS with severe brain damage and neonatal presentation leading to death of neonates within two weeks and in a German non consanguineous couple, two children had PTS-like phe-

notype with perinatal onset and died within the first week after birth. Molecular diagnosis revealed loss of function in the USP 18 gene homozygous and heterozygous variant (c.652C>T) in both families (14).

The most recent case was reported by Alsohime et al. (2020) about a Saudi infant with pseudo-TORCH syndrome 2 born to first-cousin parents after in vitro fertilization with neonatal respiratory distress, disseminated intravascular coagulopathy, without organomegaly, and grade II intraventricular hemorrhage. At the age of seven months, a molecular diagnostic test showed a homozygous splice site variant in the USP18 gene at exon 10 (c.1073+1G→A). This infant was started on ruxolitinib, a JAK1/2 inhibitor, and remained on that dose until he was three years old, with full remission of clinical signs. The kid with USP18 deficiency was the only patient who lived for at least 7 months on supportive therapy. The boy was three years old at the time when the article was published and was still receiving oral ruxolitinib. He continues to grow properly, but at a slower rate in terms of developmental milestones (4).

In the present study, two of the pregnancies ended in intrauterine death (IV-3,4) and two neonatal deaths (IV-1,2), with no medical information of IV-1. Seizures, a dilated third ventricle, corpus callosum with wavy appearance, echogenic brain parenchyma, periventricular leukomalacia, and small intestinal obstruction along with unconjugated hyperbilirubinemia were all observed in the preterm female newborn (IV-2) as described in the previous case in 2016 and 2020. A pathogenic variation observed in the homozygous and heterozygous form of USP18 (+) Exon 9 c.906 T>G in the present study was not reported so far to the best of our knowledge. The USP 18 genotype is likely to be responsible for the phenotypic distress causing intrauterine death and neonatal death in the present study. Parents (III-4,5) were heterozygous carriers for the same mutation and are healthy; thus, there was no medical indication to perform diagnostic testing to assess them.

Based on the available information, the couple was provided genetic counselling, and the recurrence risk was estimated and the options for the couple for further procedures were explained. As the couple were heterozygous carriers for the USP 18 gene mutation, they were counseled regarding the 25% of risk in each pregnancy for pseudo-TORCH syndrome 2. Extensive counselling was provided on the available management option for

this syndrome on a global scale, namely ruxolitinib therapy, which has been shown to improve clinical manifestations in afflicted children.

Conclusion

In conclusion, the present study reports the novel pathogenic mutation in USP18 gene in a pseudo TORCH syndrome 2. Thus, the improved genetic testing, pedigree analysis and genetic counselling are recommended for the diagnosis and management of rare genetic disorders in future pregnancies.

Acknowledgement

Authors would like to thank Department of Biotechnology, Government of India, New Delhi for providing financial support (No. BT/HRD/01/02/2017).

Conflict of Interest

Authors declare no conflict of interest.

References

1. Baraitser M, Brett EM, Piesowicz AT. Microcephaly and intracranial calcification in two brothers. *J Med Genet.* 1983;120(3):210-2.
2. Sakthi Seethalakshmi P, Kumaravel KS, Sampathkumar P, Babu T, Rani SR. Intracranial Calcifications With Dandy Walker Malformation. *Pediatr Oncall J.* 2019;16(2):58-9.
3. Reardon W, Hockey A, Silberstein P, Kendall B, Farag TI, Swash M, et al. Autosomal recessive congenital intrauterine infection-like syndrome of microcephaly, intracranial calcification, and CNS disease. *Am J Med Genet.* 1994;52(1):58-65.
4. Alsohime F, Martin-Fernandez M, Temsah MH, Alabdulhafid M, Le Voyer T, Alghamdi M, et al. JAK Inhibitor therapy in a child with inherited USP18 deficiency. *N Engl J Med.* 2020;382(3):256-65.
5. Richards S, Aziz N, Bale S, Bick D, Das S, Gastier-Foster J, et al. Standards and guidelines for the interpretation of sequence variants: a joint consensus recommendation of the American college of medical genetics and genomics and the association for molecular pathology. *Genet Med.* 2015;17(5):405-24.
6. Abdel-Salam GM, Zaki MS. Band-like intracranial calcification (BIC), microcephaly and malformation of brain development: a distinctive form of congenital infection like syndromes. *Am J Med Genet A.* 2009;149A(7):1565-8.
7. Knoblauch H, Tennstedt C, Brueck W, Hammer H, Vulliamy T, Dokal I, et al. Two brothers with findings resembling congenital intrauterine infection-like syndrome (pseudo-TORCH syndrome). *Am J Med Genet.* 2003;120A(2):261-5.
8. O'Driscoll MC, Daly SB, Urquhart JE, Black GC, Pilz DT, Brockmann K, et al. Recessive mutations in the gene encoding the tight junction protein occludin cause band-like calcification with simplified gyration and polymicrogyria. *Am J Hum Genet.* 2010;87(3):354-64.
9. Duncan CJ, Thompson BJ, Chen R, Rice GI, Gothe F, Young DF, et al. Severe type I interferonopathy and unrestrained interferon signaling due to a homozygous germline mutation in STAT2. *Sci Immunol.* 2019;4(42):eaav7501.
10. Malakhov MP, Malakhova OA, Kim KI, Ritchie KJ, Zhang DE. UBP43 (USP18) specifically removes ISG15 from conjugated proteins. *J Biol Chem.* 2002;277(12):9976-81.
11. Yang L, Jing Y, Kang D, Jiang P, Li N, Zhou X, et al. Ubiquitin-specific peptidase 18 regulates the differentiation and function of Treg cells. *Genes Dis.* 2020;8(3):344-52.
12. Malakhova OA, Yan M, Malakhov MP, Yuan Y, Ritchie KJ, Kim KI, et al. Protein ISGylation modulates the JAK-STAT signaling pathway. *Genes Dev.* 2003;17(4):455-60.
13. Ritchie KJ, Malakhov MP, Hetherington CJ, Zhou L, Little MT, Malakhova OA, et al. Dysregulation of protein modification by ISG15 results in brain cell injury. *Genes Dev.* 2002;16(17):2207-12.
14. Meuwissen ME, Schot R, Buta S, Oudesluijs G, Tinschert S, Speer SD, et al. Human USP18 deficiency underlies type 1 interferonopathy leading to severe pseudo-TORCH syndrome. *J Exp Med.* 2016;213(7):1163-74.