Journal of Reproduction & Infertility
Volume 23, Issue no. 3
https://doi.org/10.18502/jri.v23i3.10004

Mini Review

Check for updates

Sperm Retrieval in Non-azoospermic Patients with Persistent Ejaculation Dysfunction

Hamed Akhavizadegan [1], Mohammad Ali Sadighi Gilani [1], Naser Amirjannati [2*], Mahnaz Heidari [2]

1- Urology Department, Tehran University of Medical Scienes, Tehran, Iran
2- Reproductive Biotechnology Research Center, Avicenna Research Institute, ACECR, Tehran, Iran

** Corresponding Author:*
Naser Amirjannati,
Reproductive Biotechnology Research Center, Avicenna Research Institute, ACECR, Tehran, Iran
E-mail:
namirjannati@yahoo.com

Received: Nov. 15, 2021
Accepted: Mar. 7, 2022

Abstract

Infertility is a common disease that affects 15 to 20% of couples at some point in their lives. Among infertile couples, male factor accounts for 50% of infertile cases. Assisted reproductive techniques are the gold standard approach in case of failure in medical or surgical treatments. Moreover, the role of the urologist in these approaches is to provide appropriate sperm on the day of oocyte pick-up. However, sperm retrieval procedure is quite different in azoospermic and non-azoospermic men. Although most cases of infertile patients are not azoospermic, their ejaculation disorder prevents obtaining sperm for assisted reproductive techniques. This review article explains common problems of sperm retrieval in non-azoospermic patients with persistent ejaculatory dysfunction and introduces some management strategies. In fact, it is possible to design a classic approach for managing such patients, which definitely reduces the problems faced by clinicians as well.

Keywords: Azoospermia, Ejaculation, Infertility, Semen analysis, Sperm retrieval.
To cite this article: Akhavizadegan H, Sadighi Gilani MA, Amirjannati N, Heidari M. Sperm Retrieval in Non-azoospermic Patients with Persistent Ejaculation Dysfunction. J Reprod Infertil. 2022;23(3):141-147. https://doi.org/10.18502/jri.v23i3.10004.

Downloaded from http://www.jri.ir

Introduction

Infertility is a common disease that has received a lot of attention today and effective treatments have been developed for the disorder (1). If the disorder cannot be treated by lifestyle and behavioural modifications in the patient's life, or medical and surgical procedures, assisted reproductive techniques become the perfect solution for infertile cases (2). Sperm extraction is important when performing assisted reproductive techniques (3). Men who are candidates for sperm retrieval can often provide the ejaculated sperm and only 15 to 20% are azoospermic cases (4).

Although a limited range of infertile men are azoospermic, nearly 10 to 15%, more than 80% of literature on sperm retrieval has been dedicated to studies on this group (5). However, even a candidate for assisted reproductive technique (ART), with normal spermatogenesis and no obstruction, can impose a serious challenge for infertility centers; in other words, ejaculation disorder and obtaining the sperm make sperm retrieval a dilemma for the clinicians (6). There are also important controversies in certain groups about the best method of sperm retrieval (7). Therefore, in this article, the methods of obtaining sperm in patients with permanent ejaculation disorders are assessed and the appropriate strategy for treatment is commented and explained.

Physiology of ejaculation: After producing and storing sperm, it is transferred and inserted into a woman's vagina by ejaculation. Therefore, ejaculation plays an important role in fertility. In cases of assisted reproductive techniques and in situations where sperm are produced but ejaculation is impaired, appropriate methods will be needed to obtain sperm, which are sometimes costly and time consuming procedures. Familiarity with the

physiology and pathophysiology of ejaculation disorders helps to find a suitable treatment for these conditions. For this purpose, the relevant literature about the disorder and treatment options is discussed in this paper (8).

Although ejaculation occurs following somatic and controlled sexual activity, it is neurologically controlled by the sympathetic and parasympathetic nerves. The organs involved in ejaculation are distal part of the epididymis, vas deferens, the seminal vesicle, ejaculatory duct, the prostate, the prostatic urethra, the bladder neck, and anterior urethra, respectively. Ejaculation consists of two main parts, emission and expulsion. Emission is defined as entry of semen to posterior urethra and expulsion comprises expelling the semen out of anterior urethra (9).

During emission, sympathetic nerves stimulate contraction of muscles of epididymis, vas deference, seminal vesicles, ejaculatory duct, and drive forward the semen to the posterior urethra. These nerves simultaneously contract the bladder neck and close it in order to prevent semen leakage into bladder and its mixing with urine. Therefore, at the end of emission, the semen pools in the posterior urethra between bladder neck (internal urinary sphincter) and membranous urethra (external urinary sphincter) (10).

During expulsion, rhythmic contractions of the bulbospongiosus, ischiocavernosus, and pelvic floor muscles increase the pressure in the posterior urethra, and the semen is expelled from the urethra. The key factor is that during these contractions, the smooth muscle of the bladder neck remains closed while the striated muscle of the external sphincter opens. These contractions are controlled by somatic nerves (11).

Pathophysiology of ejaculatory disorders: Emission disorder occurs with sympathetic dysfunction. Anejaculation is the prominent clinical presentation. Damage to sympathetic fibers of the epididymis, seminal vesicles, and ejaculatory ducts can stop contractions of this pathway and the semen cannot be pushed into the posterior urethra. Retroperitoneal and pelvic surgeries, spinal cord injuries, or diseases and metabolic peripheral neuropathies such as diabetes will likely damage the emission by this mechanism (8).

Bladder neck dysfunction, causing the semen to travel into the bladder, can be due to damage to the muscles of the bladder neck during urological surgery, damage to the nerves of the bladder neck during pelvic and retroperitoneal surgeries, or as a result of peripheral neuropathies such as diabetes. Sometimes, medications with properties of alpha-blocker result in retrograde ejaculation in the presence of a healthy bladder neck and intact nerves (9).

In some cases, there is no organic reaction mechanism for anejaculation. Psychogenic and psychiatric disorders can cause severe ejaculation disorder by disrupting central neurotransmitters. In addition, psychiatric drugs can impair ejaculation by manipulating the dopamine, histamine, serotonin, and other receptors, even without the inhibitory effect of alpha-agonist (10).

Sperm retrieval in retrograde ejaculation: Ejaculation is based on rhythmic simultaneous contractions of pelvic muscles and closure of bladder neck. When the former fails, anejaculation happens and when the latter fails, retrograde ejaculation occurs. The main aetiologies of retrograde ejaculation are listed in figure 1 (12). There are several methods to retrieve sperm in retrograde ejaculation, which are summarized in table 1 (12).

Bladder neck reconstruction is highly invasive for restoring antegrade ejaculation (8). Acceptable approach for retrograde ejaculation is sperm retrieval from post-ejaculatory urine specimen if the condition cannot be improved medically as shown in figure 2 (12-14). Medical therapy is based on prescription of remedies, which physiologically help bladder neck closure and pelvic muscle contraction. The most commonly used medications are listed in table 2 (12).

Alpha agonists are the mainstay of therapy (15) with Imipramine as the most common used medication (16) which restores ejaculation after one to two weeks (12). If the medical approach fails, ART with post-ejaculatory sperm retrieval from bladder is recommended. Due to the deteriorating effect of urine on sperm, preparations are needed to decrease these negative effects such as administration of oral sodium bicarbonate for effective urine alkalinisation and buffer instillation to the bladder after voiding and before ejaculation which are presented in table 3 (12). Bladder should be emptied by voiding or catheterization before and after ejaculation in order to prevent the mixing of semen with urine. Oral treatment and vesical instillation can be used together (12, 13, 16).

Sperm retrieval in anejaculation: Anejaculation occurs because of inability of pelvic muscles to contract. The most common aetiologies are diabe-

Downloaded from http://www.jri.ir

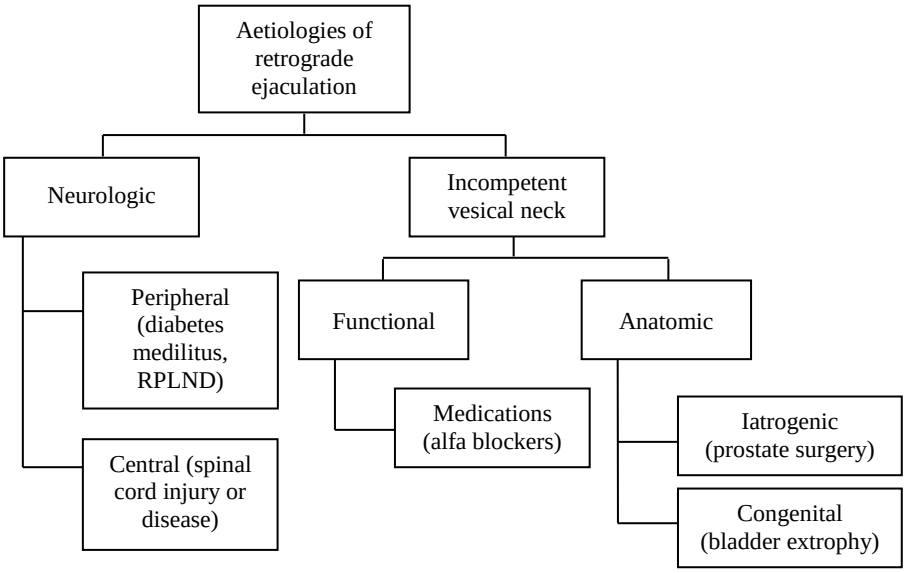

Figure 1. Aetiology of retrograde ejaculation

Table 1. Sperm retrieval in retrograde ejaculation

Restoring antegrade ejaculation	
	Medical therapy
	Bladder neck reconstruction surgery
Sperm retrieval from bladder plus ART	
	Oral treatment
	Vesical instillation

tes mellitus and RPLND (19). Available options are sorted according to their priority in table 4 (20).

Medical therapy: Sympathomimetics are drugs of choice (19) with Imipramine and pseudoephedrine as the most common prescribed ones at the same dose used for retrograde ejaculation with 40 to 60% success rate (20). In some patients, anejaculation is converted into retrograde ejaculation and the condition is easier to manage (20). Penile vibratory stimulation (PVS) has success rate of 65% to 83% in cases of anejaculation provided that spinal reflex is intact (21). Its application has been explained in spinal cord disorder section.

Electro-ejaculation: In these cases, Electro-ejaculation (EE) needs anesthesia and is more invasive (21). The technique is similar to the method used for patients with spinal cord injury.

Sperm retrieval in spinal cord injury: Severity of lesion and involved segments are main factors affecting ejaculation in spinal cord disorders (SCD). Overall, in 3 to 15% of cases, ejaculation ability is preserved but majority of patients suffer from infertility (22). The current trend is using sperm re-

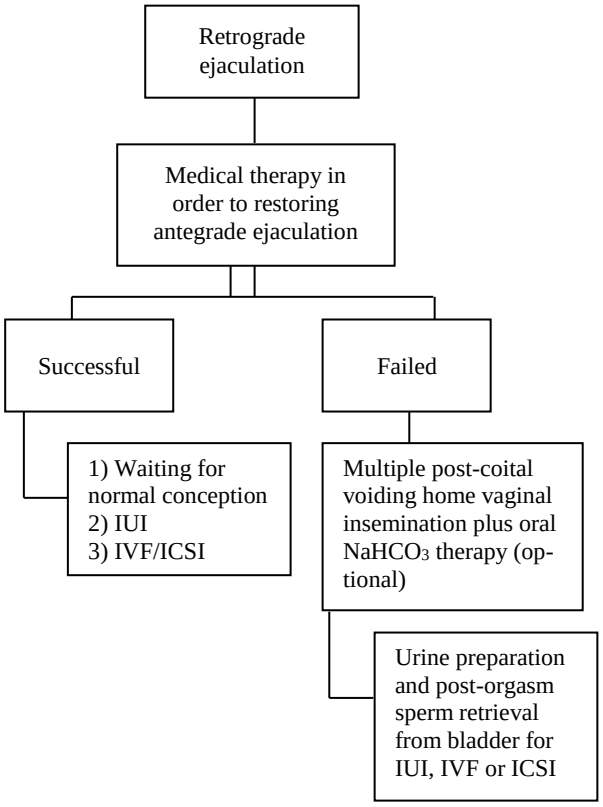

Figure 2. Sperm retrieval in retrograde ejaculation

Downloaded from http://www.jri.ir

Table 2. Medical therapy for retrograde ejaculation

Aetiology of retrograde ejaculation/medical therapy
Diabetes mellitus
- Imipramine (25 *mg* bid) - Pseudoephedrine (120 *mg* bid) - Methoxamine (5 *mg* IM)
Retroperitoneal lymph node dissection (RPLND)
- Pseudoephedrine (60 *mg* qid) - Ephedrine (100 *mg* daily) - Dextro-amphetamine (20 *mg* daily) - Phenylpropanolamine (100 *mg* daily)

Table 4. Sperm retrieval techniques in anejaculation

Sperm retrieval options in anejaculation
1) Medical therapy
2) Penile vibratory stimulation (PVS)
3) Prostate massage
4) Electro-ejaculation (EE)
5) Aspiration techniques

Table 5. Sperm retrieval methods in spinal cord disorders

Methods of sperm retrieval in spinal cord disorders
1) Prostate massage
2) Penile vibratory stimulation
3) Electro-ejaculation
4) Surgical sperm retrieval (seminal vesicle, epididymis, or testis)

trieval and ART. However, in cases who are reluctant to use these services but have enough time and patience, combination of alpha agonist and PVS helps to collect semen (23). The available options are listed in table 5 (22, 24). There is no difference in quality of sperm and pregnancy rate among patients who used sperm with retrieval techniques and the methods are selected based on feasibility and the degree of invasiveness (25-27). The recommended approach to retrieve sperm from patients with spinal cord disorders is demonstrated in figure 3 (22, 24, 28).

Although antegrade ejaculation might be restored by alpha agonists (26), PVS and EE in SCD are highly recommended for retrograde ejaculation and concomitant bladder preparation is mandatory (22). Applying any techniques for retrieving sperm can induce autonomic dysreflexia and life threatening hypertension (26) in patients with lesion higher than T7 (31). Continuous or frequent blood pressure monitoring and administration of sublingual nifedipine (20 *mg*) or captopril (25 *mg*), 15 *min* before manipulation are preventive measures (32, 33).

Prostate massage: Naturally, there is no sperm in ejaculatory duct and seminal vesicles. However, in these patients, accumulated sperm occupy seminal vesicle and ejaculatory duct due to inability in regular semen evacuation. Although the prostate massage is successful in 70% of patients, fewer than half of these cases have sperm in their semen. Even IUI can be recommended depending on the quality of sperm retrieved (34). Sperm can be found in 80% of lesions higher than T10 and 18% of lesions lower than T10, which raises a debate on the application of the method in the second group (35).

Penile vibratory stimulation: PVS success rate has been reported to be around 12 to 80% in heterogeneous populations with SCD (34). The strategies to increase success rate of PVS are listed in table 6. If the response does not occur after 15 *min*, it is unlikely to achieve success with continuing the procedure and it is better to proceed to the next step (37). Relative contraindications of PVS are penile prosthesis and severe irritation of the glans (36).

Electro-ejaculation: In the absence of any major anorectal problems, the technique is applied (10-

Table 3. Preparation techniques for retrograde ejaculation

Oral treatment
- 1 to 1.5 *gr* or 1-2 tea spoons of $NaHCO_3$ (baking soda), the night before and the morning of ejaculation - Acetazolamide (500 *mg* qid) one day before ejaculation - Potassium citrate (640 *mg*) one day before ejaculation
Vesical instillation
- Media human tubal fluid (HTF) with 5% human serum albumin (25 to 50 *ml*) - For patients with urethral catheter or suprapubic catheter, changing catheter and bladder irrigation two to three times with normal saline (17)

Downloaded from http://www.jri.ir

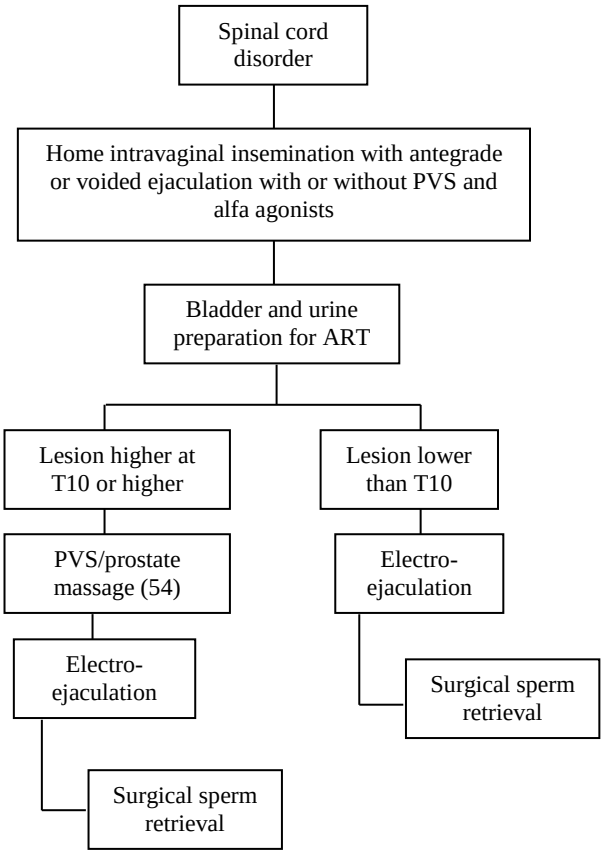

Figure 3. Sperm retrieval in SCD

Table 6. Strategies to increase success rate of PVS

Strategy
1) Using vibrator set at maximal settings (35), frequency of 110 HTZ and amplitude of 3.55
2) Simultaneous abdominal functional electrical stimulation (35)
3) Application of 2 sandwich vibrators (34)

15 v, 30 mA) for 3 to 5 *min* (37). The lowest possible voltage is induced first and then increased gradually. It is possible to obtain more antegrade semen by intermittent rather than continuous stimulation (32, 33). Most of the patients can tolerate the procedure without any anesthesia; however, pain sensation level should be assessed to ensure that patients would feel no pain (32, 33). Ejaculation can occur without erection; therefore, milking and catheterization must be done at the end of any failed procedure and specimen should be checked for sperm (17). The procedure must be stopped if rectal temperature reaches 38°*C* or in voltages higher than 30 (37).

Surgical techniques: Through common techniques including sperm aspiration from seminal vesicle, epididymis or testis, enough sperm can be obtained. However, spermatogenesis deteriorates gradually after having 12 years of neurological disorders. If the aspiration techniques fail, micro-TESE and conventional TESE are recommended in testes sized less than 10 *ml* and larger than 10 *ml* (38). Sperm cryopreservation is not recommended in SCD because using fresh sperm results in significantly better findings (65% *vs.* 25%). Sperm cryopreservation is only recommended when there is risk of azoospermia or in the first two weeks of trauma when quality of sperm has not been deteriorated (36).

Conclusion

One group of candidates for sperm retrieval in ART are non-azoospermic patients with persistent ejaculatory dysfunction. In literature, the methods dealing with these conditions have been discussed sporadically. In this review, it was shown that designing a classic approach for these patients is a feasible alternative. In fact, applying these approaches in infertility centers reduces the problems of patients and clinicians.

Conflict of Interest

Authors declare no conflict of interest.

References

1. Qi L, Liu YP, Zhang NN, Su YC. Predictors of testicular sperm retrieval in patients with non-obstructive azoospermia: a review. J Int Med Res. 2021;49(4):3000605211002703.
2. Eslamian G, Amirjannati N, Rashidkhani B, Sadeghi MR, Baghestani AR, Hekmatdoost A. Adherence to the western pattern is potentially an unfavorable indicator of asthenozoospermia risk: a case-control study. J Am Coll Nutr. 2016;35(1):50-8.
3. Shin DH, Turek PJ. Sperm retrieval techniques. Nat Rev Urol. 2013;10(12):723-30.
4. Akhavizadegan H. Benefit of sperm freezing before radical orchiectomy. Clin Transl Oncol. 2009;11 (12):849-50.
5. Eslamian G, Amirjannati N, Rashidkhani B, Sadeghi MR, Baghestani AR, Hekmatdoost A. Dietary fatty acid intakes and asthenozoospermia: a case-control study. Fertil Steril. 2015;103(1):190-8.
6. Phillips E, Carpenter C, Oates RD. Ejaculatory dys-

Downloaded from http://www.jri.ir

function. Urol Clin North Am. 2014;41(1):115-28.

7. Mostafa T, Abdel-Hamid IA. Ejaculatory dysfunction in men with diabetes mellitus. World J Diabetes. 2021;12(7):954-74.
8. Eslamian G, Amirjannati N, Rashidkhani B, Sadeghi MR, Hekmatdoost A. Nutrient patterns and asthenozoospermia: a case-control study. Andrologia. 2017; 49(3).
9. Pizzol D, Trott M, Grabovac I, Yang L, Barnett Y, Parris C, et al. Ejaculation disorders in male patients with cancer: a systematic review and meta-analysis of prevalence. J Urol. 2021;206(6):1361-72.
10. Trinchieri M, Trinchieri M, Perletti G, Magri V, Stamatiou K, Cai T, et al. Erectile and ejaculatory dysfunction associated with use of psychotropic drugs: a systematic review. J Sex Med. 2021;18(8): 1354-63.
11. Salonia A, Bettocchi C, Boeri L, Capogrosso P, Carvalho J, Cilesiz NC, et al. European association of urology guidelines on sexual and reproductive health-2021 update: male sexual dysfunction. Eur Urol. 2021;80(3):333-57.
12. Ebner T, Shebl O, Mayer RB, Moser M, Costamoling W, Oppelt P. Healthy live birth using theophylline in a case of retrograde ejaculation and absolute asthenozoospermia. Fertil Steril. 2014;101(2):340-3.
13. Marmar JL, Praiss DE, DeBenedictis TJ. Postcoital-voiding insemination: technique for patients with retrograde ejaculation and infertility. Urology. 1977;9(3):288-90.
14. Hsiao W, Deveci S, Mulhall JP. Outcomes of the management of postchemotherapy retroperitoneal lymph node dissection–associated anejaculation. BJU Int. 2012;110(8):1196-200.
15. Revenig L, Leung A, Hsiao W. Ejaculatory physiology and pathophysiology: assessment and treatment in male infertility. Transl Androl Urol. 2014; 3(1):41-9.
16. Ibrahim E, Brackett NL, Lynne CM. Advances in the management of infertility in men with spinal cord injury. Asian J Androl. 2016;18(3):382-90.
17. Perrin J, Saïas-Magnan J, Lanteaume A, Thiry-Escudié I, Serment G, Bladou F, et al. [Initial results of a novel technique for sperm retrieval in male infertility due to refractory retrograde ejaculation]. Prog Urol. 2011;21(2):134-8. French.
18. Lu S, Cui Y, Li X, Zhang H, Hu J, Liu J, et al. Sperm retrieval in anejaculatory diabetic men who failed in drug treatment and penile vibratory stimulation during blood sugar under control. Andrologia. 2014;46(4):370-3.
19. Kondoh N. Ejaculatory dysfunction as a cause of infertility. Reprod Med Biol. 2012;11(1):59-64.
20. Mehta A, Sigman M. Management of the dry ejaculate: a systematic review of aspermia and retrograde ejaculation. Fertil Steril. 2015;104(5):1074-81.
21. Marina S, Marina F, Alcolea R, Nada J, Pons MC, Grossmann M, et al. Triplet pregnancy achieved through intracytoplasmic sperm injection with spermatozoa obtained by prostatic massage of a paraplegic patient. Hum Reprod. 1999;14(6):1546-8.
22. Hadiji N, Benbouzid R, Previnaire JG, Leblond C, Mieusset R, Enjalbert M, et al. [Evaluation of treatment of erectile and ejaculatory dysfunction in a series of 90 spinal cord injured]. Prog Urol. 2013; 23(17):1489-93. French.
23. Arafa MM, Zohdy WA, Shamloul R. Prostatic massage: a simple method of semen retrieval in men with spinal cord injury. Int J Androl. 2007;30 (3):170-3.
24. Ohl DA, Sonksen J, Menge AC, McCabe M, Keller LM. Electroejaculation versus vibratory stimulation in spinal cord injured men: sperm quality and patient preference. J Urol. 1997;157(6):2147-9.
25. Engin-Üstün Y, Korkmaz C, Duru NK, Başer İ. Comparison of three sperm retrieval techniques in spinal cord-injured men: pregnancy outcome. Gynecol Endocrinol. 2006;22(5):252-5.
26. Qiu Y, Wang LG, Zhang LH, Zhang AD, Wang ZE. Quality of sperm obtained by penile vibratory stimulation and percutaneous vasal sperm aspiration in men with spinal cord injury. J Androl. 2012; 33(5):1036-46.
27. Fode M, Ohl DA, Sønksen J. A step-wise approach to sperm retrieval in men with neurogenic anejaculation. Nat Rev Urol. 2015;12(11):607-16.
28. Leduc BE. Treatment of infertility in 31 men with spinal cord injury. Can J Urol. 2012;19(5):6432-6.
29. Sonksen J, Ohl DA. Penile vibratory stimulation and electroejaculation in the treatment of ejaculatory dysfunction. Int J Androl. 2002;25(6):324-32.
30. Soler JM, Previnaire JG, Plante P, Denys P, Chartier-Kastler E. Midodrine improves orgasm in spinal cord-injured men: the effects of autonomic stimulation. J Sex Med. 2008;5(12):2935-41.
31. Nancy LB. Infertility in men with spinal cord injury: research and treatment. Scientifica (Cairo). 2012;2012:578257.
32. Brackett NL, Kafetsoulis A, Ibrahim E, Aballa TC, Lynne CM. Application of 2 vibrators salvages

Downloaded from http://www.jri.ir

ejaculatory failures to 1 vibrator during penile vibratory stimulation in men with spinal cord injuries. J Urol. 2007;177(2):660-3.

33. Sonksen J, Fode M, Löchner-Ernst D, Ohl DA. Vibratory ejaculation in 140 spinal cord injured men and home insemination of their partners. Spinal Cord. 2012;50(1):63-6.

34. Goetz LL, Stiens SA. Abdominal electric stimulation facilitates penile vibratory stimulation for ejaculation after spinal cord injury: a single-subject trial. Arch Physical Med Rehabil. 2005;86(9): 1879-83.

35. Trofimenko V, Hotaling JM. Fertility treatment in spinal cord injury and other neurologic disease. Transl Androl Urol. 2016;5(1):102-16.

36. Reignier A, Lammers J, Splingart C, Redhead D, Labat JJ, Mirallié S, et al. Sperm cryopreservation and assisted reproductive technology outcome in patients with spinal cord injury. Andrologia. 2018; 50(1).

37. Iwahata T, Shin T, Shimomura Y, Suzuki K, Kobayashi T, Miyata A, et al. Testicular sperm extraction for patients with spinal cord injury related anejaculation: a single-center experience. Int J Urol. 2016;23(12):1024-7.

Downloaded from http://www.jri.ir