

Ectopic Molar Pregnancy: A Rare Entity

Borah, Tulon^{1*}; Raphael, Vandana²; Panda, Subrat¹; Saharia, Pallab²

1- Department of Obstetrics and Gynecology, North Eastern Indira Gandhi Regional Institute of Health & Medical Sciences (NEIGRIHMS), Shillong, Meghalaya, India

2- Department of Pathology, North Eastern Indira Gandhi Regional Institute of Health & Medical Sciences (NEIGRIHMS), Shillong, Meghalaya, India

Abstract

Introduction: Ectopic molar pregnancy is a rare occurrence and consequently not often considered as a diagnostic possibility. In this article, an attempt was made to stress on the need for histopathological examination and follow up of every case of ectopic pregnancy. This was substantiated with the help of a case report.

Case Presentation: A 30-year-old gravida 4, para 3, pregnant woman with a 7-week history of amenorrhea attended hospital with abdominal pain. Per vaginal examination revealed a tender left adnexal mass measuring 4x4 cm and on ultrasonography there was a live fetus corresponding to a 7-week and 6 days gestation with free fluid in the pelvic cavity. Laparotomy, revealed a ruptured left tubal ectopic pregnancy and histopathological examination was suggestive of a molar pregnancy.

Conclusion: Although rare, molar changes can occur at any site of an ectopic pregnancy. Clinical diagnosis of a molar pregnancy is difficult but histopathology is the gold standard for diagnosis.

Keywords: Ectopic molar pregnancy, Ectopic pregnancy, Histopathology, Human chorionic gonadotropin, Molar pregnancy.

To cite this article: Borah T, Raphael V, Panda S, Saharia P. Ectopic Molar Pregnancy: A Rare Entity. *J Reprod Infertil.* 2010;11(3):201-3.

* Corresponding Author:
Dr. Tulon Borah,
Department of Obstetrics
and Gynecology, North
Eastern Indira Gandhi
Regional Institute of
Health and Medical
Sciences (NEIGRIHMS),
Mawdiangdiang, Shillong,
Meghalaya, India.

E-mail:
borahatulon@gmail.com

Received: May 1, 2010
Accepted: Jun. 27, 2010

Introduction

The incidence of partial or complete hydatidiform mole is approximately 1 in 500 to 1 in 1000 pregnancies (1). Molar changes may also be found in ectopic pregnancies. Its malignant potential is similar to that of an intrauterine molar pregnancy (2). Molar changes could be either partial or complete and the treatment is surgical combined with chemotherapy. Follow-up is usually done by serial serum human chorionic gonadotropin (β -hCG) titrations. Although ultrasonography is useful in the diagnosis of uterine molar pregnancies, there is a chance of missing this diagnosis in cases of an ectopic molar pregnancy.

Case Presentation

A 30-year-old female patient, gravida 4, para 3, was admitted to North Eastern Indira Gandhi Regional Institute of Health and Medical Sciences (NEIGRIHMS), Shillong, India with a 7-week

history of amenorrhea followed by an episode of mild bleeding per vaginum. She also had abdominal pain 1 week prior to the presentation. On examination, her vital signs were stable with no pallor or edema. Per abdominal examination revealed tenderness over the left iliac fossa, without any guarding or rigidity. Per vaginal examination showed a normal-sized uterus and a tender left adnexal mass measuring 4x4 cm.

Her hemoglobin concentration was 8.6% gr/dl and the urine pregnancy test was positive. Trans-abdominal ultrasonography confirmed the finding of a left tubo-ovarian mass denoting a live fetus corresponding to 7 weeks and 6 days of gestation with free fluid in the pelvic cavity.

Keeping in view the above findings, decision for exploratory laparotomy was made. However, such hemodynamically stable patients could have been managed by laparoscopy in the presence of the

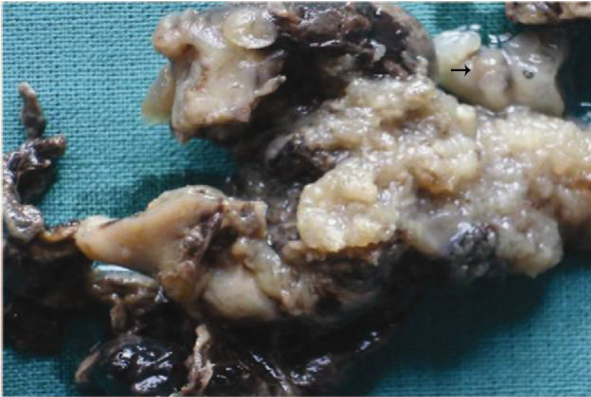


Figure 1. Ruptured tube showing fetus and placental tissue with molar changes

required facility and expertise.

During the operation, hemoperitonium was found with a normal uterus, an intact right-sided fallopian tube and a ruptured left tubal ectopic pregnancy. Consequently, left-sided salpingectomy was performed to maintain proper homeostasis.

Gross examination showed grey brown tissue, measuring 6x4x2 cm with moles ranging in size from 1 to 3 mm and a fetus corresponding to 6 to 7 weeks of gestation (Figure 1). The specimen was then subjected to histopathological examination (Figure 1).

On histological examination, there were chorionic villi showing circumferential trophoblastic proliferation, hydropic changes and karyorrhexis. Based on these findings, the possibility of a molar pregnancy was thought and serum β -hCG level determination was asked. Postoperatively, on the day of surgery, serum β -hCG was 5308 mIU/ml. Her post-operative period was otherwise uneventful, but she was followed up by weekly serum β -hCG measurements. The tests showed a decreasing trend and turned negative at the end of the 6th week. Barrier contraception was advised for at least 1 year during which she was also on regular follow-ups.

Discussion

Clinically, tubal molar pregnancy mimics normal tubal ectopic pregnancy and, therefore, makes the diagnosis difficult (3). However, provisional diagnosis is made during surgery and histopathological examination can determine the final diagnosis.

Molar changes may even be found in cervical pregnancies (4, 5). Molar changes can be detected by transvaginal color Doppler ultrasonography. Magnetic resonance imaging is also helpful in localizing the lesion.

Conservative fertility-sparing management was found successful in a reported case of cervical molar pregnancy (5).

Cornual pregnancy itself is a very rare condition and a challenging diagnosis to make. Rupture of the horn does not usually take place until the twelfth week of gestation but, when it does, there is nearly always severe bleeding which makes the condition extremely dangerous. Molar changes are even found in cornual pregnancies (6, 7). Reported cases of molar changes in ovarian pregnancy are also found in the literature (8).

Molar ectopic pregnancy becomes even more difficult to diagnose when it occurs in heterotopic pregnancies, where the patient may present with shock, weeks after evacuation of the intrauterine pregnancy (9). The condition might then be confused with degenerated fibroid seen during pregnancy. Although extremely rare, an extra-uterine molar pregnancy should form part of the differential diagnoses in cases of intra-uterine pregnancy complicated by the presence of a pelvic mass, vascularity and high levels of serum β -hCG (10).

Monitoring β -hCG titers following conservative management of suspected ectopic pregnancies is important, not only to diagnose persistent ectopic gestation, but also to rule out the presence of malignant trophoblastic diseases (11). The current trend in the treatment of ectopic pregnancies is through conservative surgery and monitoring of β -hCG titers to avoid missing a choriocarcinoma developing in an ectopic gestation, even though this is a very rare condition (12). Mediastinal metastasis of choriocarcinomas following ectopic pregnancies cause dyspnoea, pleural effusion and thoracic pain (13).

One extensive study on routine pre-evacuation ultrasound diagnosis of hydatidiform mole suggests that ultrasonography identifies less than 50% of hydatidiform moles. Detection rates are, however, higher for complete compared to partial moles, and improve even further after the 14th week of gestation (14).

Histopathological examination of conception

products remains the current gold standard for the diagnosis of gestational trophoblastic neoplasia. There is also a possibility of over-diagnosis by histological examination, especially in early ectopic tubal pregnancies, due to a more florid extra-villous trophoblastic proliferation compared with evacuated uterine products of conception (1). Extra caution should be taken to strictly apply the morphological criteria of circumferential trophoblastic proliferation, hydropic changes, scalloped villi and stromal karyorrhexis for diagnosis (15).

Conclusion

Ectopic molar pregnancy is a rare condition, which can occur at any place in the pelvic cavity. Invasive mole and choriocarcinoma might even follow such a pregnancy. However, ultrasonography might not be able to fully diagnose ectopic molar pregnancies, leaving histopathological examination of the conception products the current gold standard for the diagnosis.

Acknowledgement

No Conflict of interest existed for the authors of this article.

References

1. Sebire NJ, Lindsay I, Fisher RA, Savage P, Seckl MJ. Overdiagnosis of complete and partial hydatidiform mole in tubal ectopic pregnancies. *Int J Gynecol Pathol.* 2005;24(3):260-4.
2. Abdul MA, Randawa AJ, Shehu SM. Ectopic (tubal) molar gestation: report of two cases. *Niger J Clin Pract.* 2008;11(4):392-3.
3. Chauhan S, Diamond MP, Johns DA. A case of molar ectopic pregnancy. *Fertil Steril.* 2004;81(4):1140-1.
4. Wee HY, Tay EH, Soong Y, Loh SF. Cervical hydatidiform molar pregnancy. *Aust N Z J Obstet Gynaecol.* 2003;43(6):473-4.
5. Aytan H, Caliskan AC, Demirturk F, Koseoglu RD, Acu B. Cervical partial hydatidiform molar pregnancy. *Gynecol Obstet Invest.* 2008;66(2):142-4.
6. Chauhan MB, Chaudhary P, Dahiya P, Sangwan K, Sen J. Molar cornual ectopic pregnancy. *Acta Obstet Gynecol Scand.* 2006;85(5):625-7.
7. Zite NB, Lipscomb GH, Merrill K. Molar cornual ectopic pregnancy. *Obstet Gynecol.* 2002;99(5 Pt 2):891-2.
8. Church E, Hanna L, New F, Uku A, Awad H, Watson AJ. Ovarian molar pregnancy. *J Obstet Gynaecol.* 2008;28(6):660-1.
9. Leung F, Terzibachian JJ, Chung Fat B, Lassabe C, Knoepffler F, Maillet R, et al. [Heterotopic ovarian hydatidiform mole. A case report]. *Gynecol Obstet Fertil.* 2009;37(9):749-51. French.
10. Snyman LC. Case report of an intra-uterine pregnancy complicated by an ectopic invasive molar pregnancy. *Southern Afr J Gynae Oncol.* 2009;1(2):69-70.
11. Rotas M, Khulpateea N, Binder D. Gestational choriocarcinoma arising from a cornual ectopic pregnancy: a case report and review of the literature. *Arch Gynecol Obstet.* 2007;276(6):645-7.
12. Bakri YN, Amri A, Mulla J. Gestational choriocarcinoma in a tubal ectopic pregnancy. *Acta Obstet Gynecol Scand.* 1992;71(1):67-8.
13. Kagel T, Lemburg SP, Müller KM, Laczkovics A, Nicolas V, Heyer CM. [Mediastinal metastasis of a tubal choriocarcinoma following ectopic pregnancy as a rare cause of thoracic pain]. *Zentralbl Gynakol.* 2006;128(2):90-4. German.
14. Fowler DJ, Lindsay I, Seckl MJ, Sebire NJ. Routine pre-evacuation ultrasound diagnosis of hydatidiform mole: experience of more than 1000 cases from a regional referral center. *Ultrasound Obstet Gynecol.* 2006;27(1):56-60.
15. Burton JL, Lidbury EA, Gillespie AM, Tidy JA, Smith O, Lawry J, et al. Over-diagnosis of hydatidiform mole in early tubal ectopic pregnancy. *Histopathology.* 2001;38(5):409-17.