

Cervical Cancer Along with Unknown Cirrhosis: A Misdiagnosed Case

Soheila Aminimoghaddam^{1*}, Fatemeh Mahmoudzadeh², Andisheh Maghsoudnia³

1- Firoozgar Hospital, Iran University of Medical Sciences, Tehran, Iran

2- Mazandaran University of Medical Sciences, Sari, Iran

3- Tarbiat Modarres University, Tehran, Iran

Abstract

Background: Cervical cancer is the second most common malignancy in women worldwide. Vaginal bleeding and vaginal discharge are the most common symptoms. Although ascites has been reported in cases with cervical cancer, it is due to other causes such as ovarian metastasis.

Case Presentation: A 78-year-old diabetic woman who presented with ascites and abdominopelvic mass was misdiagnosed with ovarian cancer and treated with neoadjuvant chemotherapy followed by radical hysterectomy and adjuvant radiotherapy. However, pathology confirmed locally advanced cervical cancer stage IV in this patient. She was discharged from the hospital three weeks after surgery with no serious complications.

Discussion: Considering all signs and symptoms to reach a verdict would reduce such malpractices and consequently lead to select the best management and treatment.

Keywords: Diabetes mellitus, Liver cirrhosis, Misdiagnosed case, Ovarian neoplasms, Uterine cervical neoplasms.

To cite this article: Aminimoghaddam S, Mahmoudzadeh F, Maghsoudnia A. Cervical Cancer Along with Unknown Cirrhosis: A Misdiagnosed Case. *J Reprod Infertil.* 2015;16(3):174-177.

* Corresponding Author:

Soheila

Aminimoghaddam,
Gynecology Ward,
Firoozgar Hospital,
Tehran, Iran

E-mail:

Dr_aminimoghaddam@
yahoo.com

Received: Apr. 29, 2014

Accepted: Sept. 7, 2014

Introduction

Cervical cancer is the second most common malignancy in women worldwide (1). The initiating event in cervical cancer is HPV infection and immunosuppression is a risk factor (2). Several studies proposed that diabetes mellitus (DM) could increase the risk of developing cervical cancer (3-5).

The most common symptoms are abnormal vaginal bleeding and discharge; patients with advanced disease may present with pelvic pain and bowel or urinary symptoms (6). Although ascites has been reported in the cases with cervical cancer, it is due to other causes such as ovarian metastasis (7, 8).

Many studies were done to compare different treatments of locally advanced cervical cancer. Finally, primary cisplatin-based chemoradiotherapy was recommended as the best current treat-

ment of it (9, 10). Recently, a new study has reported that neoadjuvant chemotherapy followed by radical hysterectomy (NAC+RH) improves survival of patients with locally advanced cervical cancer in comparison to concurrent chemoradiotherapy (CCRT) (11).

In this study, a case was reported who was consulted by gynecologic oncology service because of pelvic mass and ascites. Our case was a menopausal woman who had diabetes mellitus and was a new case of cirrhosis. Neoadjuvant chemotherapy was suggested for her because she had comorbidity and suffered from cirrhosis and it was presumed that she had ovarian cancer. During laparotomy after chemotherapy, our misdiagnosis was discovered because she had a pelvic mass in upper part of cervix that was fixed to bladder. It was highly suspicious for cervical cancer and frozen

section evaluation confirmed that. Therefore, radical hysterectomy was done and she received several courses of radiotherapy after surgery.

Case Presentation

Our case was a 78-year-old diabetic woman who presented with ascites and abdominopelvic mass and was admitted into Firoozgar hospital in Tehran, Iran on June 2010. She also complained of weight loss about 8kg in the last 3 months, nausea, vomiting, anorexia, dysuria, and fever. She had diabetes mellitus since ten years ago and took Metformin, Glibenclamide, Losartan, and Atorvastatin. On physical examination, her abdomen was distended with fluid wave and there was a palpable 25 cm × 20 cm mass in hypogastric part. During bimanual pelvic examination, a large, solid, irregular, fixed pelvic mass was found which occupied the whole pelvis. The exocervix had normal appearance.

Laboratory data revealed a normocytic anemia, pyuria, hematuria, mild hyponatremia, hypoalbuminemia, increased prothrombin time, and elevated serum level of cancer antigen 125 (CA125). Human papillomavirus DNA test (PCR) was negative in this patient. Cytologic evaluation of ascites fluid was positive for malignancy. Pap test was negative. Abdominal ultrasound (US) reported a small-sized liver (4 cm) with increased paranchymal echogenicity, bilateral hydronephrosis, huge amount of free fluid in abdominopelvic area, and a large pelvic mass with irregular border which US was not able to identify its origin. Abdominopelvic computed tomography (CT) scan showed ascites and frozen pelvis with no evidence of metastasis and lymphadenopathy (Figures 1-2). The fibroscan examination confirmed the liver cirrhosis.

Our first diagnosis was ovarian cancer; therefore, three cycles of neoadjuvant chemotherapy with

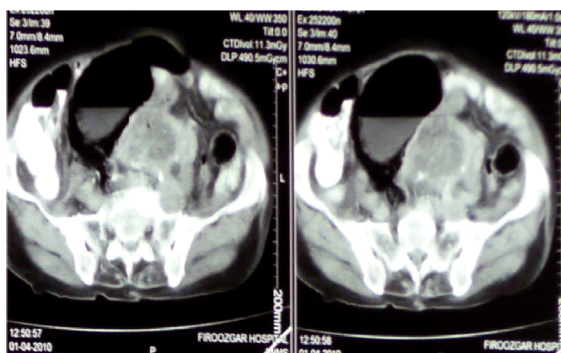


Figure 1. Large mass was shown in pelvic CT scan

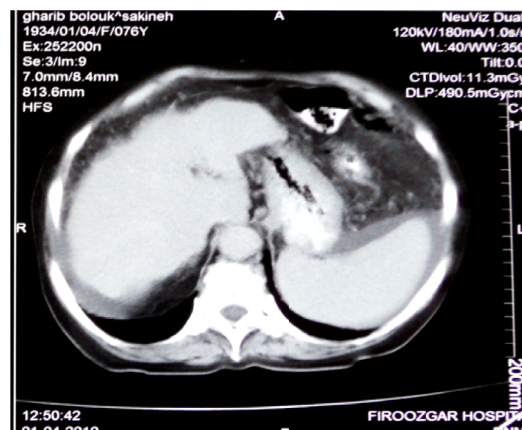


Figure 2. Cirrhosis was revealed by abdominal CT scan

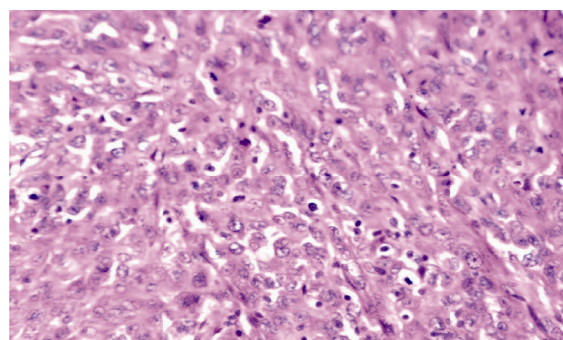


Figure 3. Pathology: invasion to myometrium

Taxol 175 mg/m² and Carboplatin 300 mg/m² were performed. Laparotomy was performed 3 weeks after the last chemotherapy cycle. During exploration of pelvis, a mass was seen in upper part of cervix that was fixed to bladder. Bladder mucosa was involved. Frozen section evaluation confirmed the cervical cancer diagnosis. The disease was at stage 4 and therefore radical hysterectomy was prepared for the patient and performed removing parameters and 1/3 of proximal vagina. She was in menopause and bilateral salpingo-oophorectomy was done and the tissue samples were sent for pathologic evaluations. The histopathology of removed cervix showed localized advanced squamous cell carcinoma, stage IV (Figures 3-4).

Staging of ovarian cancer was surgicopathological but staging cervical cancer is clinical. There was a misdiagnosis about our case and after pelvic exploration during laparotomy, correct diagnosis was reached and radical hysterectomy was performed.

The patient was discharged three weeks later with no complication. She has received twelve courses of EPR (External Pelvic Radiotherapy)

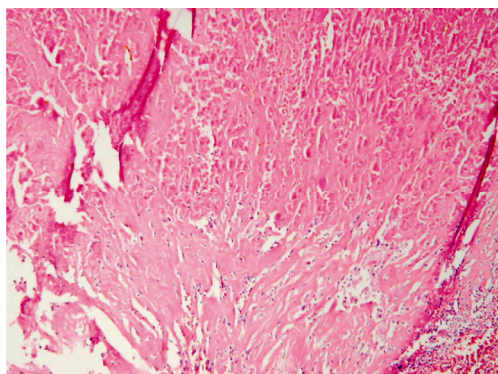


Figure 4. Pathology: invasion to the bladder

after surgery till now. Our patient was successfully treated with NAC+RH+EPR (Neo Adjuvant chemotherapy + Radical Hysterectomy + External Pelvic Radiotherapy). She has remained disease free up to now. She was followed up with serial clinical examination, Pap smear, and abdominopelvic CT scan.

Discussion

In this case presentation, an old diabetic and newly-diagnosed cirrhotic woman was reported who presented with abdominopelvic mass, ascites, and elevated CA125. She was misdiagnosed with ovarian cancer and treated with NAC+RH+EPR. Findings during laparotomy and pathologic evaluation of specimens confirmed locally advanced cervical cancer, stage IV in this patient.

Locally advanced cervical cancer is a usual presentation in unscreened women. The most common symptoms are abnormal vaginal bleeding, postcoital bleeding, and vaginal discharge. In advanced stages of the disease, it presents with pelvic or lower back pain, and urinary and bowel involvement symptoms (6, 12). While Abdulhathi et al. reported cervical cancer cases presented with ascites, they were due to ovarian metastasis (7, 8). No study could be found to report ascites due to cervical cancer alone or with concomitant cirrhosis. Approximately, 5 percent of ascites cases have more than one cause, such as cirrhosis plus peritoneal carcinomatosis (13). In ultrasonography, the presence of solid non hyperechoic ovarian mass and ascites together could be suggestive of ovarian malignancy but metastases to the ovary should be considered as a differential diagnosis. Metastatic disease accounts for 6 to 9 percent of ovarian malignancies and the uterus is also a common primary site for ovarian metastases (14, 15). Therefore, if there is any doubt in diagnosis,

image-guided biopsy of the peritoneum or omental cake may help to exclude a non ovarian malignancy (16). In literature review, Zhan et al., Jee et al., and also Kuriki et al. showed that DM increased the risks for developing cervical cancer but there is no evidence to offer, such an association with ovarian cancer (3-5). Similarly, immunosuppression is one of the risk factors of cervical cancer that can be caused by cirrhosis and DM in this case. Human papillomavirus (HPV) infection is the most common causal agent of cervical cancer and can be detected in 99.7 percent of cervical cancers (17, 18). Moreover, CA125 is not specific for ovarian cancer. It is also increased in adenocarcinoma of the cervix, liver disease and cirrhosis, ascites, diabetes, and in approximately 1 percent of healthy women (19).

If the patient was diagnosed correctly with cervical cancer stage IV, she needed to be treated by CCRT rather than NAC+RH, especially in this case (9, 10). She presented with ascites and had comorbid disease and accordingly was not a good candidate for initial surgery (20). Although Yin has recently reported that NAC+RH improve the long-term disease-free survival (DFS) and overall survival (OS) of patients with locally advanced cervical cancer compared with CCRT, the patients in his sample were all in stage IB2-IIB and this case was in stage IV (11).

Conclusion

In conclusion, the combination of abdominopelvic mass, ascites, elevated CA125, and negative human papillomavirus infection in conjunction with lack of attention to epidemiologic hints, DM history, bilateral hydronephrosis, and newly diagnosed cirrhosis misled us to diagnosis of ovarian cancer in this patient. It seems that considering all signs and symptoms to reach a verdict would reduce such malpractices and consequently lead to selecting the best management and treatment. It seems necessary to refine our differential diagnosis using complementary workup and confirm our final diagnosis before choosing the appropriate treatment for each patient.

Conflict of Interest

Authors declare no conflict of interest.

References

1. Solomon D, Breen N, McNeel T. Cervical cancer screening rates in the United States and the potential

- impact of implementation of screening guidelines. *CA Cancer J Clin.* 2007;57(2):105-11.
2. International Collaboration of Epidemiological Studies of Cervical Cancer. Comparison of risk factors for invasive squamous cell carcinoma and adenocarcinoma of the cervix: collaborative reanalysis of individual data on 8,097 women with squamous cell carcinoma and 1,374 women with adenocarcinoma from 12 epidemiological studies. *Int J Cancer.* 2007; 120(4):885-91.
 3. Zhan YS, Feng L, Tang SH, Li WG, Xu M, Liu TF, et al. Glucose metabolism disorders in cancer patients in a Chinese population. *Med Oncol.* 2010;27(2):177-84.
 4. Kuriki K, Hirose K, Tajima K. Diabetes and cancer risk for all and specific sites among Japanese men and women. *Eur J Cancer Prev.* 2007;16(1):83-9.
 5. Jee SH, Ohrr H, Sull JW, Yun JE, Ji M, Samet JM. Fasting serum glucose level and cancer risk in Korean men and women. *JAMA.* 2005;293(2):194-202.
 6. Subramaniam A, Fauci JM, Schneider KE, Whitworth JM, Erickson BK, Kim K, et al. Invasive cervical cancer and screening: what are the rates of unscreened and underscreened women in the modern era? *J Low Genit Tract Dis.* 2011;15(2):110-3.
 7. Nazari Z, Behtash N, Gilani MM, Ganjoei TA. Cervical carcinoma simulating advanced ovarian cancer. *Eur J Surg Oncol.* 2007;33(1):123-4.
 8. Abdulhathi MB, Al-Salam S, Kassis A, Ghazal-Aswad S. Unusual presentation of cervical cancer as advanced ovarian cancer. *Arch Gynecol Obstet.* 2007;276(4):387-90.
 9. Chemoradiotherapy for Cervical Cancer Meta-analysis Collaboration (CCCMAC). Reducing uncertainties about the effects of chemoradiotherapy for cervical cancer: individual patient data meta-analysis. *Cochrane Database Syst Rev.* 2010;(1):CD008285.
 10. Committee on Practice Bulletins-Gynecology. ACOG practice bulletin. Diagnosis and treatment of cervical carcinomas, number 35, May 2002. *Obstet Gynecol.* 2002;99(5 Pt 1):855-67.
 11. Yin M, Zhao F, Lou G, Zhang H, Sun M, Li C, et al. The long-term efficacy of neoadjuvant chemotherapy followed by radical hysterectomy compared with radical surgery alone or concurrent chemoradiotherapy on locally advanced-stage cervical cancer. *Int J Gynecol Cancer.* 2011;21(1):92-9.
 12. Rose PG. Locally advanced cervical cancer. *Curr Opin Obstet Gynecol.* 2001 Feb;13(1):65-70.
 13. Uddin MS, Hoque MI, Islam MB, Uddin MK, Haq I, Mondol G, et al. Serum-ascites albumin gradient in differential diagnosis of ascites. *Mymensingh Med J.* 2013;22(4):748-54.
 14. Tempe A, Singh S, Wadhwa L, Garg A. Conventional and color Doppler sonography in preoperative assessment of ovarian tumors. *Int J Gynaecol Obstet.* 2006;92(1):64-8.
 15. Skirnisdottir I, Garmo H, Holmberg L. Non-genital tract metastases to the ovaries presented as ovarian tumors in Sweden 1990-2003: occurrence, origin and survival compared to ovarian cancer. *Gynecol Oncol.* 2007;105(1):166-71.
 16. Hewitt MJ, Anderson K, Hall GD, Weston M, Hutson R, Wilkinson N, et al. Women with peritoneal carcinomatosis of unknown origin: Efficacy of image-guided biopsy to determine site-specific diagnosis. *BJOG.* 2007;114(1):46-50.
 17. Waggoner SE. Cervical cancer. *Lancet.* 2003;361(9376):2217-25.
 18. Bailey J, Cymet TC. Planning for the HPV vaccine and its impact on cervical cancer prevention. *Compr Ther.* 2006;32(2):102-5.
 19. Leary A, Pautier P, Tazi Y, Morice P, Duvillard P, Gouy S, et al. [The molecular biology of epithelial ovarian cancer]. *Bull Cancer.* 2012;99(12):1161-73. French.
 20. Geisler JP, Linnemeier GC, Thomas AJ, Manahan KJ. Nutritional assessment using prealbumin as an objective criterion to determine whom should not undergo primary radical cytoreductive surgery for ovarian cancer. *Gynecol Oncol.* 2007;106(1):128-31.