

## Posterior Urethral Valve: An Unusual Cause of Primary Male Infertility

Jude Orumuah Agbugui \*, Oisamoren Omokhudu

- Department of Surgery, University of Benin Teaching Hospital, Benin City, Nigeria

### Abstract

**Background:** Posterior urethral valve presenting in adulthood is uncommon. This can be an unusual cause of primary male infertility as a result of abnormalities in sexual function.

**Case Presentation:** This report describes a 40 year old man who presented to us on account of inability to impregnate his wife after 2 years of marriage. History revealed poor stream of urine since childhood and passage of scanty ejaculate during intercourse. A micturating cystourethrogram revealed dilated posterior urethra in keeping with posterior urethral valves. Endoscopic valve ablation was done with subsequent improvement in ejaculate volume and urine stream. His spouse achieved pregnancy thereafter.

**Conclusion:** In this report, it was found that adult posterior urethral valve though uncommon may be a cause of male infertility. Restoration of fertility potential can be achieved following valve ablation.

**Keywords:** Male infertility, Posterior urethral valves, Retained ejaculate.

**To cite this article:** Agbugui JO, Omokhudu O. Posterior Urethral Valve: An Unusual Cause of Primary Male Infertility. *J Reprod Infertil.* 2015;16(2):113-115.

\* Corresponding Author:

Jude Orumuah Agbugui,  
Department of Surgery,  
University of Benin,  
Teaching Hospital, Benin  
City, Nigeria

E-mail:  
orumuah@yahoo.com

Received: Sept. 22, 2014

Accepted: Nov. 18, 2014

### Introduction

Posterior urethral valve (PUV) is a congenital malformation found in males that is characterized by the presence of abnormal obstructing membranes in the posterior urethra. The exact embryology of the condition is not completely understood but it is believed to arise mainly as a result of an anomalous insertion of the mesonephric duct into the primitive fetal cloaca (1). This leads to an obstruction in the flow of urine through the urethra with the classic presentation of poor stream at birth. It is the most common cause of bladder outlet obstruction in male children and can be complicated by urinary tract infection (UTI), structural changes in the urinary tract and impaired renal function (2, 3).

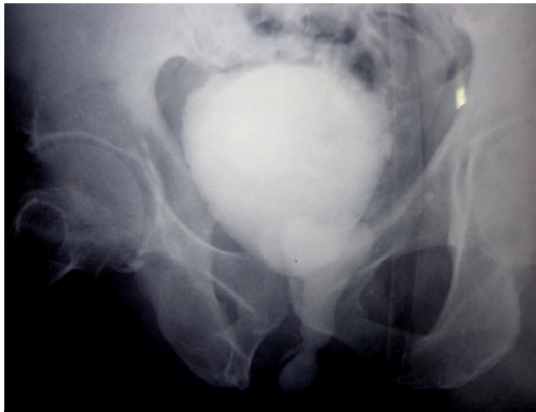
The diagnosis of the condition may be suggested prenatally following a maternal abdominal scan in the presence of hydronephrosis and oligohydramnios. Postnatally, diagnosis is made usually with the aid of micturating cystourethrogram during evaluation of voiding dysfunction (2). In cases with mild obstruction, presentation may be delayed until later in childhood (2, 4). However,

PUV in the adult male is reported to be an unusual finding (5, 6). This may occur in patients with mild obstructing valves who do not develop severe complications of the disease. This presentation may be an unusual cause of urinary and sexual symptoms (7).

In this paper, an attempt was made to present the management of a 40 year old man with primary infertility due to PUV causing retained ejaculate during sexual intercourse.

### Case Presentation

A 40 year old presented to the urology unit of the University of Benin Teaching Hospital, Nigeria in April, 2013 with complaint of inability to impregnate his wife after 2 years of marriage. The couple lived together with regular sexual intercourse (2-3 times weekly). However, there was associated passage of scanty and sometimes absent ejaculate during intercourse with trickling of seminal fluid few minutes thereafter. The patient had a history of poor urinary stream since childhood which he ignored. There was no history of ure-



**Figure 1.** Micturating cystourethrogram of the patient showing dilated posterior urethra

thral trauma but the patient had several episodes of UTI which was treated in a community hospital.

Examination findings were essentially normal except for mild left hydrocele. The peak flow rate was 8 ml/s. An assessment of urethral stricture leading to primary male infertility was initially entertained. However, contrast studies by means of a retrograde urethrogram and a micturating cystourethrogram showed a dilated posterior urethra suggestive of PUV with associated bladder trabeculations (Figure 1). Abdominal ultrasonography revealed mild bilateral hydronephrosis. The patient was not able to produce sufficient semen for proper seminal fluid analysis (SFA), on the two occasions the test was requested. Urine culture did not yield any growth of organisms while serum urea, electrolytes and creatinine values were within normal limits ( $\text{Na}^+$  138 mEq/l,  $\text{K}^+$  4.2 mEq/l, Urea 30 mg/dl and Creatinine 1.1 mg/dl). He subsequently had urethrocystoscopy which confirmed type 1 of PUV that was ablated during the procedure using a diathermy bugbee electrode. After removal of catheter the next day, there was significant improvement of the urine stream with a peak flow rate of 15 ml/s.

Four weeks later during follow up visit, the patient reported having good volume of ejaculate during intercourse with further improvement in urine stream. His SFA report after 6 weeks of valve ablation was satisfactory, with values within normal ranges (volume; 3.5 ml, count;  $38 \times 10^6/\text{ml}$ , motility; 55%, morphology; 40%). The serum electrolytes, urea and creatinine concentrations remained normal during the follow up. Abdominal scan after 3 months of valve ablation still showed

evidence of mild hydronephrosis. However, he was subsequently able to impregnate his wife.

### Discussion

Most cases of PUV are usually diagnosed either before birth with the aid of a prenatal scan or soon after birth following evaluation of a male child with poor urinary stream (2). Though cases with mild obstructing valves may present later in childhood, the diagnosis of the condition is uncommon in adulthood (5, 6).

Presentation in adulthood may occur due to the presence of a mild form of the disease devoid of the life threatening complications noted in children with the severe form. In Nigeria, many patients with the disease still present late (8). This may be facilitated by ignorance of the symptoms of the disease by parents, guardians and affected individuals as well as paucity of specialized health-care. Our patient presented on account of inability to impregnate his wife and was found to have associated poor urinary stream and passage of scanty ejaculate in the course of evaluation. The diagnosis was suggested with radiological finding of a dilated posterior urethra and confirmed on urethrocystoscopy. The patient had recurrent UTI but there was no associated impairment in renal function seen in severe cases (3, 4).

PUV as a cause of male infertility is rare (9). Obstruction to antegrade flow at the posterior urethra occurs not only with urine but with semen after normal ejaculation. As such, sufficient amount of semen may not be introduced within the vagina during intercourse leading to a reduction in the likelihood of fertilization. The patient was not able to impregnate his wife after 2 years of marriage despite regular sexual intercourse. This may have been due to retention of significant amount of seminal fluid within the posterior urethra.

Satisfactory outcome following valve ablation was achieved with improvement in urine stream and ejaculate volume. He had normal SFA values 6 weeks after valve ablation and was able to impregnate his wife in the course of follow up.

### Conclusion

Though rare, PUV presenting in adulthood may be a cause of male infertility. Patients presenting in the fertility clinic with a history of scanty ejaculate and reduced urinary stream should be evaluated in this regard. Restoration of fertility

potential can be achieved after successful valve ablation.

#### Conflict of Interest

Authors declare that there is no conflict of interest.

#### References

1. Krishnan A, de Souza A, Konijeti R, Baskin LS. The anatomy and embryology of posterior urethral valves. *J Urol*. 2006;175(4):1214-20.
2. Warren J, Pike JG, Leonard MP. Posterior urethral valves in Eastern Ontario - a 30 year perspective. *Can J Urol*. 2004;11(2):2210-5.
3. Atwell JD. Posterior urethral valves in the British Isles: a multicenter B.A.P.S. review. *J Pediatr Surg*. 1983;18(1):70-4.
4. Schober JM, Dulabon LM, Woodhouse CR. Outcome of valve ablation in late-presenting posterior urethral valves. *BJU Int*. 2004;94(4):616-9.
5. Maranya GA. Posterior urethral valves in the adult: report of two cases. *East Afr Med J*. 2004;81(8):430-2.
6. Culty T, Delongchamps NB, Dominique S, Servin F, Ravery V, Boccon-Gibod L. Posterior urethral valves in adult with Down syndrome. *Urology*. 2006;67(2):424.e1-424.e2.
7. Opsomer RJ, Wese FX, Dardenne AN, Van Cangh PJ. Posterior urethral valves in adult males. *Urology*. 1990;36(1):35-7.
8. Ikuerowo SO, Balogun BO, Akintomide TE, Ikuerowo AO, Akinola RA, Gbelee HO, et al. Clinical and radiological characteristics of Nigerian boys with posterior urethral valves. *Pediatr Surg Int*. 2008;24(7):825-9.
9. Ahmed A, Bello A, Mbibu NH, Maitama HY, Kalayi GD. Epidemiological and aetiological factors of male infertility in northern Nigeria. *Niger J Clin Pract*. 2010;13(2):205-9.